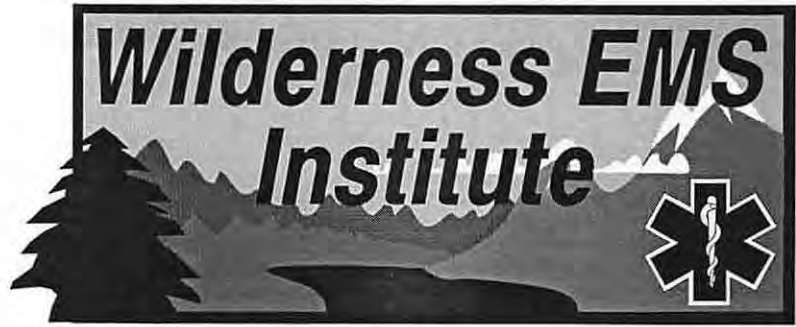

Appalachian Search and Rescue Conference  
Center for Emergency Medicine of Western Pennsylvania

# Wilderness EMT Lesson Plan

## Part V-a: Wilderness Surgical Problems, General

Draft Version 1.61, August 15, 1994

Comments to:

Charles E. Stewart, M.D., Task Group V-a Leader

3433 Oak Creek Drive West Colorado Springs, CO 80906

**Task Group:** Jeffrey S. Anderson, M.D.; Stuart M. Carpenter, EMT; John M. Chandler, M.D.; Sherwood Chetlin, M.D.; Keith Conover, M.D.; Bob Gedekoh, M.D.; Jody Gerard, M.D.; Carol Gilbert, M.D.; Elizabeth Honingford, M.D.; Robert Koester, EMT; Andrew Pietzman, M.D.; Richard A. Saunders, M.D.; Eric Weiss, M.D.; David M. Tauber, EMT-P; and Ricardo Townsend, M.D.

© 1989, 1994 by ASRC-CEM WEMCDP/WEMSI

This Draft contains material proprietary to the ASRC-CEM Wilderness EMS Institute; it is preliminary and may contain significant errors, so it should **not** serve as a reference. It may not be reproduced whole or in part without written permission. It is not to be circulated except to Staff and Consultants to the WEMSI, and students at our classes. However, a future draft version of this material **will** be made public.

**Project Coordinator:**

Keith Conover, M.D. 36 Robinhood Road  
Pittsburgh, PA 15220-3014 412-561-3413

---

## **Verbose Outlines**

We develop our WEMT Lesson Plans in a **verbose outline format** (what you see here). Why? Because the material is new to enough reviewers that the usual terse ("telegraphic") lesson plan format might be incomprehensible or misleading.

Our Task Groups use these "verbose" outlines. Each part of the WEMT curriculum (about twenty in all) has a Task Group of five to twenty selected consultants. A Coordinator guides the Task Group in revising the section.

Each Task Group provides references to support its statements and for further reading. They also provide glossary entries for any new terms they introduce. (New, that is, to a reader with basic EMT and SAR training.)

Background material that should appear in the Textbook (see below), but instructors need not present in class, will appear *in a small, italic font*.

---

## **Splitting the Outlines**

When the outline satisfies the Task Group, it goes to our **Editorial Board**. This Board includes officers of the Appalachian Search and Rescue Conference and Center for Emergency Medicine of Western Pennsylvania, our two sponsors. It also includes experts in emergency medicine, search and rescue, and education. The Editorial Board reviews the verbose outline, and requests any necessary revisions. Once it is acceptable to the Board, we reformat the outline, into two distinct new versions.

We rewrite the material in the standard lesson plan format, which becomes a terse "telegraphic" outline. This version will be briefly reviewed by the Project Coordinator and then released to the public. It is the result of extensive review and testing, and will be used in all our classes. But, we still publish it as a draft, because we expect many good suggestions from the public. We distribute these drafts as widely as possible. After each year of public review, the Task Groups reviews comments, and submits revisions to the Editorial Board. Once all outlines have withstood a year of public scrutiny, we will prepare a single comprehensive curriculum with a Course Guide. We will continue to review and revise the curriculum regularly.

---

## **On to a Textbook**

As explained above, once the Editorial Board approves the verbose outline, we split it into two versions. Besides the terse teaching outline, it will also become the basis for a textbook chapter. The

Project Coordinator is the textbook Editor-in-Chief, and works closely with the Task Groups to consolidate and revise the verbose outlines into a comprehensive textbook. All who have contributed to the curriculum will be acknowledged as contributors. The textbook will be commercially published when completed. Until the textbook is available, we will distribute the verbose outlines or drafts of the textbook at classes.

---

## **Notes: Wilderness Surgical Problems**

This part of the curriculum is a condensed summary of surgical, as opposed to medical, problems. The criteria for including a problem are: (1) the problem is common in the wilderness and can be treated by a WEMT; (2) the problem is important to recognize, even if just to initiate the decision to abort the task and return to base, or to start an immediate evacuation; (3) management of the problem in the wilderness differs from that on the street; or (4) the problem might develop during a long evacuation.

The treatment for many surgical conditions involves the use of over-the-counter or prescription medications or minor surgical procedures. The choice of wilderness medical kit drugs and their use, and surgical procedures, is up to the WEMT's medical director and appropriate state laws and regulations. However, medications are carried and used by most wilderness travelers, including search and rescue team members, and the WEMT, as the team medical expert, must understand proper use of these medications, and interactions and problems to expect from their use. The Pharmacology section summarizes this information, but specific surgical indications are covered here.

This section potentially overlaps with the sections on *General Medicine*, *Assessment*, *Wilderness Medical Problems*, and *Wilderness Trauma*. We have indicated where a topic is already covered in one of these sections.

Note that there are two Task Group Leaders for this section, and it is divided into V-a and V-b sections. Educational objectives 1-29 have been assigned to the general surgical section (V-a) and objectives 30-38 to the orthopedic section (V-b).

---

**V. Wilderness Surgical Problems, part a: General**

---

**A. Educational Objectives**

1. Outline the differences in prognosis and management between closed head injury and skull fracture.
2. Define "concussion," "increasing intracranial pressure," and "the lucid interval," and outline the diagnostic features of each.
3. Outline the pathophysiology and major characteristics of:
  - a. epidural bleeds;
  - b. subdural bleeds;
  - c. subarachnoid bleeds; and
  - d. intracerebral bleeds.
4. Outline important points in the diagnosis and wilderness management of:
  - a. midface fractures;
  - b. nasal fractures, including the significance of a septal hematoma;
  - c. zygomatic arch (zygoma) fractures;
  - d. blowout fractures;
  - e. jaw fractures;
  - f. other facial fractures; and
  - g. laryngeal trauma.
5. Describe the diagnosis and wilderness treatment for pulmonary contusion.
6. Describe the complications that may be caused by a myocardial contusion.
7. Describe the diagnosis and wilderness management of an isolated rib fracture.
8. Describe problems in the wilderness management of patients with blunt abdominal trauma including:
  - a. the two organs most likely to be injured;
  - b. the classic history for a patient with a subcapsular hemorrhage of the spleen; and
  - c. proper management for a team member with minor blunt abdominal trauma.
9. Outline the wilderness management of penetrating abdominal trauma, including protruding abdominal contents.
10. Outline the problems associated with straddle injuries and their wilderness management.
11. Give two examples of common wilderness medical kit medications that should be avoided during pregnancy.
12. Outline a standard normal vaginal delivery procedure as would be performed by an obstetrician in the wilderness.
13. Define "threatened abortion" and describe the management of a woman with a threatened abortion.
14. Demonstrate the ability to clean a wound using proper irrigation.
15. Present arguments for and against closure of wounds in the wilderness, including:
  - a. scarring and limitation of function; and
  - b. the risk of anaerobic and other infections.
16. Describe the effect, on wound infection rates, of the time from injury until closure, and define:
  - a. primary intention;
  - b. primary closure;
  - c. secondary intention;
  - d. delayed closure; and
  - e. delayed primary closure.
17. Define "high-risk" and "low-risk wounds" for the wilderness context, give examples of each, and describe the wilderness management of each.

18. Describe the purpose and method of wound irrigation, and list fluids that are suitable for wound irrigation.
19. Describe proper procedures for caring for a wound in the wilderness, and outline factors that affect the likelihood of wound infection.
20. Outline the proper wilderness management of friction blisters.
21. Outline the proper wilderness management of impaled objects, including splinters.

---

### **B. Disclaimer**

**Recommendations for medical treatment in this curriculum are presented for training purposes only. We have attempted to ensure that all recommendations are consistent with current medical practices, but all care provided by WEMTs must be by the order of a physician. Your physician medical director must set protocols and standing orders, and you must follow them, even if they conflict with the recommendations in this curriculum.**

---

### **C. Closed Head Injury**

1. A common worry after a blow to the head is the possibility of a **skull fracture**. However, from a neurosurgical and emergency medicine point of view, a skull fracture with no deformity is not a serious injury. To be sure, a nondisplaced skull fracture may be an indicator of an injury forceful enough to cause serious problems **inside** the skull (or in the neck, or elsewhere). But intracranial injuries are a result of the mechanism of injury and its force, not usually a direct result of a nondisplaced skull fracture. A depressed or open skull fracture is a neurosurgical emergency; a face fracture with airway involvement is an ENT

emergency; a skull fracture with CSF leaking from the nose or ear is a set-up for meningitis; and, a cranial fracture with damage to the eye is an ophthalmologist's emergency. However, as one ER doc says when he explains to his patients why he's not ordering skull X-rays: "We don't cast skull fractures." To summarize: you shouldn't worry overmuch about missing a nondisplaced skull fracture. If you do detect a skull fracture, though, you should consider injury inside the skull more likely; watch the patient closely.

2. On the other hand, you **should** worry about **intracranial injuries**. They are both more serious than skull fractures and more difficult to detect. The skull is solid, but the brain inside is mushy and full of delicate blood vessels just waiting to rupture. Even minor trauma can, on occasion, cause a traumatic intracranial bleed. As taught in the EMT-Basic course, there are (at least) four types of intracranial bleed: epidural, subdural, subarachnoid, and intracerebral. There are some differences between them that you should take time to learn.
  - a. **Epidural bleeds** are commonly caused by trauma to the middle meningeal artery, a large artery that leaves the skull and enters the brain tissue in the area of the temple. This may rupture because of a skull fracture here, or from a sudden force pulling the brain away from the skull (e.g., a climber's fall, a rock impacting on a helmet, or the impact of an aircraft crashing). The bleeding is usually rather brisk, and rapid neurological deterioration usually precedes death.
  - b. **Subdural bleeds** are usually due to rupture of a small "bridging vein" that connects the brain to venous sinuses (large, irregular veins) in the thick dura layer of the meninges surrounding the brain. This venous bleeding is slower than the arterial bleeding that occurs

with an epidural bleed, and the bleeding often stabilizes and forms a clot without killing the patient.

- c. **Subarachnoid bleeds** are often the result of traumatic rupture (or more commonly, spontaneous nontraumatic rupture) of a pre-existing aneurysm of one of the large blood vessels supplying the brain. Since the subarachnoid space freely communicates around the brain and into the spinal cord, irritation of the meninges in the neck and back often causes a stiff neck as well as a severe headache. Unlike the other kind of bleeds, where brain damage is confined to a single area and the neurological exam often shows a focal deficit, subarachnoid bleeds usually show diffuse neurological findings, such as confusion, or hyperreflexia and upgoing toes.
  - d. **Intracerebral bleeds** may occur from rupture of an aneurysm or from a stroke accompanied by bleeding (a "hemorrhagic stroke") as well as from trauma. The exact type of neurological symptoms that result depend on the location and extent of the bleed. Intracerebral bleeds from trauma, however, are often accompanied by severe brain swelling and often lead to severe impairment or death.
3. Unconsciousness (or a decreased level of consciousness) is common after a blow to the head. As a WEMT, you need to know three common clinical pictures after head injury.
    - a. First is a "**concussion**." The term concussion is old, and means many things to many people. In specific neurologic and emergency medicine terms, however, concussion has a very specific meaning: a brief loss of some neurologic function after a blow to the head. Another part of the definition requires that there be no anatomic damage, i.e., a CAT scan or MRI scan would show no evidence of one of the intracranial bleeds described above. Those with a concussion may continue to have a headache, confusion, or some other mild neurologic deficit, but their neurological status should never get worse. A person who deteriorates after a blow to the head has something other than a simple concussion.
    - b. Next is the syndrome of **increasing IntraCranial Pressure (ICP)**. Increasing ICP can come from any of the bleeds described above, or from diffuse swelling of the brain after trauma. A decreasing level of consciousness is the hallmark of increasing ICP. Other signs may be remembered as **Cushing's Triad** (named after a famous surgeon who first described these three signs of increasing ICP). The triad includes tachypnea, hypertension, and bradycardia. Thus, a typical patient with increasing ICP would have decreasing level of consciousness, increasing respirations and BP, and decreasing pulse.
    - c. One classic clinical syndrome you should know is "**the lucid interval**." An example would be a climber who falls, and is "knocked out" for a few seconds; later, the climber wakes up, at least to a degree, and then gradually becomes confused and lapses into unconsciousness. The initial unconsciousness is a concussion. The later deterioration is due to an epidural hematoma or other serious intracranial problem.
    - d. Intracranial bleeding may be delayed by days or even weeks after a significant head injury, so WEMTs must be carefully monitor the neurological status of all head injury patients, even if the injury occurred days ago.<sup>1,2,3</sup>
  4. Management of a head-injured patient is similar on the street and in the wilderness. There is very little that you can do for a person with a severe head injury

in either location. If the patient has a significant brain injury or bleed, rapid evacuation and transport to a hospital with neurosurgeons on staff is the chief treatment.

- a. Keep the patient calm and comfortable, assure a good airway, and be prepared for vomiting. If you have medications to treat hypertension, don't be eager to use them in a patient with a head injury. The high blood pressure may be a compensatory response, forcing blood into areas of the brain that might otherwise not be perfused with blood.
- b. If the patient is deteriorating rapidly, you can try maneuvers to decrease intracranial pressure. These include elevating the head, hyperventilating the patient, giving mannitol, giving furosemide, and treating hypertension. All of these may cause decreased perfusion in injured areas of the brain, however, and you should reserve them for patients who are going rapidly downhill. (I.e., treat only patients who go from talking to deeply unconscious.)<sup>4</sup>

---

#### **D.Facial Trauma**

1. **Face fractures** may be massive or simple. For massive injury, the first priority is always protection of the airway, and is usually best managed by positioning. Those with simple face fractures should be evacuated, but may often walk out with assistance. Team members with certain simple fractures (e.g., zygoma fractures where the person can still open the mouth without difficulty, or nondisplaced nasal fractures with no septal hematoma) may even continue with a search and rescue task if the pain is not severe.
2. **Midface fractures** are uncommon, but you should always check for them in a patient with a facial injury. A standard test is to hold the forehead in one hand, and with the other hand on the teeth of the upper jaw, check for gross instability of the upper jaw. These are commonly called "LeFort" fractures, named after a doctor who developed a classification for these fractures.
3. **Nasal fractures** are generally well-splinted by swelling, and need no treatment other than ice and elevation (sleeping on two pillows). Decongestant nasal spray or oral decongestants may aid breathing through the swollen nose, particularly at night. Nosebleeds can generally be managed by direct pressure on the nares for 5-10 minutes. You should inspect the inside of the nose for evidence of a **septal hematoma**, which is a blood clot under the mucosa of the middle of the nose. If this is not drained surgically within a day or two, the body will reabsorb it; and, may very well reabsorb the cartilage of the septum along with it, making the nose collapse inwards on itself. On the athletic field, a common layman's treatment for a markedly displaced nasal fracture is to grasp it firmly and put it back into approximately normal shape. Once swelling sets in (minutes to hours), reduction must usually be delayed until the swelling goes away, a matter of days. Reducing the nose before swelling sets in has one major advantage: the person may be able to breathe through the nose much better, and immediate reduction is usually less painful than reduction days later. However, reduction might start nasal bleeding that might be difficult to stop, and thus is seldom recommended by ENT doctors.
4. The **zygoma** (zygomatic arch) is the bone just in front of the ear and posterior to the cheekbone. A depressed fracture of this bone may trap the **masseter** muscle, preventing the patient from

opening the mouth all the way. This fracture must be fixed in the operating room, but can be done at any time within several days of the injury.

5. **Blowout fractures of the orbit** come from a blunt blow to the eye. The pressure is transmitted by the fluid in the eye, and causes the inferior portion of the orbit to "blow out" into the maxillary sinus below. The eye may appear sunken compared with the other eye. The **inferior rectus muscle** (the bottom eye muscle) may become trapped in the fractured area, causing the eye to "stick" when the person tries to look upwards. This may be obvious to the examining WEMT, or may be more subtle, causing diplopia (double vision) only on upward gaze. Thus, the importance of checking for **extraocular motions** during the physical examination after head trauma. As with the zygoma fracture, the blowout fracture (with or without inferior rectus trapping) requires surgery within a few days, and is cause for an evacuation, but not an urgent one.
6. **Jaw fractures** may be gross or subtle. A person with bilateral mandibular fractures may be physically unable to keep the tongue from obstructing the airway in the supine (flat on back) position, but may be able to maintain an airway perfectly well if transported lying face-down, or if the jaw is mechanically held up. Any patient who says, after trauma to the jaw, "my teeth don't fit right," has a jaw fracture until proven otherwise. A cravat, roller gauze, or ace wrap from under the chin to the top of the head usually provide adequate splinting. However you immobilize a jaw fracture, you should be able to remove it in a hurry if the person vomits.
7. You may encounter a variety of **other facial fractures**. As long as the airway is not compromised, and there is no evidence of decreasing level of conscious-

ness, the patient should be evacuated promptly but not urgently. When one of the sinuses may be involved, standard care includes the use of an oral antibiotic such as amoxicillin to prevent sinus infection.

8. Trauma to the neck may cause swelling or **fracture of the larynx**. When this causes airway obstruction, the only field treatment is intubation or a cricothyroid membrane puncture, even though these techniques may be difficult with a fractured or edematous larynx. (Note that a needle cricothyroid membrane puncture is not an adequate airway for a long evacuation; a surgical cricothyroid membrane airway is necessary.) For laryngeal edema after blunt trauma, an albuterol or similar inhaler may help by reducing edema.

---

### **E. Chest Trauma and Rib Fractures**

1. Treatment of **flail chest, sucking chest wounds, and pneumothorax** are the same in the wilderness as on the street, except that arrangements to place a chest tube may sometimes be appropriate prior to evacuation. (I.e., it may be appropriate to call in an advanced provider to do so.) Any patient with a pneumothorax or hemothorax that is detectable in the field, and who is facing a long evacuation, should have a chest tube placed prior to the evacuation. If a wilderness paramedic and chest tube are not available, however, you should not postpone the evacuation.
2. Those with a severe blow to the chest may develop a **pulmonary contusion**, with symptoms similar to pneumonia. Treatment is good pulmonary care, pursed-lip breathing by the patient, and possibly oxygen. Pursed-lip breathing means holding the lips in a "whistling" manner while breathing out. This keeps some positive airway pressure in the

lungs, and helps keep damaged alveoli and small airways from collapsing.

3. Those who have had a severe blow to the sternum may develop a **myocardial contusion**. This may result in irregular cardiac rhythms, and EKG monitoring is indicated. Myocardial contusion may also (rarely) result in congestive heart failure or cardiac tamponade. The wilderness treatment for cardiac arrhythmias, CHF, or tamponade is the same as on the street. Patients with congestive heart failure may be treated with diuretics such as furosemide (e.g., Lasix®). While not a problem on the street, a large output of urine from furosemide usually causes large loss of potassium. Caring for such a patient during a long evacuation, you should think about changing to IV fluids with potassium (e.g., LR instead of NS).
4. A patient who has had a blow to the chest and who has one or two ribs that are point tender probably has **rib fractures**. (For such isolated rib fractures, physical examination is generally better than X-ray for diagnosis.) In any patient with potential rib fractures, you must carefully examine the chest for any evidence of a pneumothorax.
  - a. A team member with only one or two isolated rib fractures, but no other injury, may walk out with assistance.
  - b. A team member with a rib fracture may find relief from strips of tape placed firmly along the rib for splinting. However, you should let the patient use rib taping **only** if the patient will be active. In an inactive patient, taping broken ribs, or using a rib belt, will add to the voluntary muscular splinting due to pain, and may lead to atelectasis and pneumonia.<sup>5,6</sup>
  - c. The mainstay of treatment for isolated rib fractures is adequate pain relief to allow good lung expansion.

## **F. Blunt Abdominal Trauma**

1. Evaluating blunt abdominal trauma is a challenge in the wilderness. This is especially true, given that you will need to examine team members who have sustained blunt abdominal trauma from minor falls and other injuries. Another difficulty is that many multi-trauma patients have blunt abdominal trauma that is not suggested by physical exam.
2. When a climber takes a long fall and is caught by a belay rope around the waist or attached to a harness, blunt abdominal injury is likely. We may make some estimates based on the similarity to seat-belt injuries, for which we have good data.<sup>7,8</sup> Of patients with organ injury due to blunt trauma, the most commonly injured organ is the spleen, which was injured in about 1/3 of cases. About two thirds of these spleen injuries are isolated (not associated with other organ injuries). The next most commonly injured organ is the liver. We may expect that these two injuries would be particularly common in a patient who took a fall on a waist loop.
3. The physical diagnosis of blunt abdominal trauma is difficult. Blood or localized tenderness found on the rectal exam are diagnostic but rare.
  - a. Suppose you are confronted with the following. A team member who fell has slight bruising and tenderness over the left lower ribs, has slight left upper quadrant tenderness on your exam, but has an otherwise benign abdominal exam. Later the team member starts complaining of orthostatic lightheadedness. This is a classic history for a rupture of the spleen, with bleeding somewhat contained by the capsule around the spleen. Splenic damage such as this can occur after minor trauma. With or without additional minor trauma, the capsule around the spleen may finally rupture, causing



massive internal bleeding and death. Other than avoiding trauma to the spleen, there is no field treatment.

- b. In alert patients, the most reliable signs of significant organ damage are:
  - (1) pain and tenderness;
  - (2) a point of maximal tenderness;
  - (3) pain on abdominal movement; and
  - (4) rebound tenderness.<sup>9</sup>
4. The key to your evaluation of team members with possible blunt intra-abdominal trauma is **repeated exams**. If the team member has a benign exam, including a normal orthostatic pulse (and BP, if a BP cuff is available), you should let the team member continue with the task, with cautions to immediately report any orthostatic lightheadedness or increasing abdominal discomfort. You should reevaluate the team member every hour or two. Any increasing symptoms, development of orthostasis by pulse or BP, or increasing tenderness on abdominal exam, should cause a prompt evacuation to base.

---

### **G. Penetrating Abdominal Trauma**

1. Management of penetrating abdominal trauma is much the same in the wilderness as on the street: protect from further injury and transport. However, there are a few differences in how you must protect from injury, due to the long transport time.
2. On the street, EMTs are taught to cover protruding intestines with an occlusive dressing to prevent evaporation. They are taught not to replace the intestines into the abdominal cavity. This makes sense when transport times are short. Replacing the intestines (and omentum, folds of fatty tissue attached to the intestines) might introduce foreign material or bacteria into the abdominal cavity. An EMT also might damage the

intestines while replacing them, releasing large amounts of stool and fecal bacteria into the abdominal cavity.

3. The intestines depend on the protective environment of the abdominal cavity, and over an extended period outside the abdomen, would tend to dry out, even with an occlusive dressing. Too, if the intestines are twisted or constricted by the abdominal wound, leaving them out for a long period might complicate an abdominal wound with bowel obstruction.
4. We recommend that you should replace protruding intestines if it can be done without additional trauma, after gentle irrigation with clean water or saline solution. You should carefully note any evidence of rupture of the intestines (a fecal smell, or visible stool). Cover the wound with a sterile dressing damp with 1% povidone-iodine (e.g., Betadine®) solution (a 1:10 dilution of the standard 10% solution), then an occlusive dressing. If IV or IM antibiotics are available, you should administer them in accordance with your protocols for abdominal trauma.

---

### **H. Straddle Injuries**

1. Straddle injuries (caused by falling onto a log or rock with the legs outstretched) can cause a variety of injuries, including pelvic fractures, muscle strains, and genital trauma. Cold (ice or snow) applications help reduce swelling.
2. If urinary retention is a problem, a Foley urinary catheter is appropriate, after a rectal exam to check for a high-riding prostate (in men).

---

### **I. Pregnancy\***

1. Pregnancy is a rare but important complication of wilderness patients.

2. **Women who are pregnant must avoid many drugs** because of their effects on the fetus. Here are a few examples:
    - a. For pain, acetaminophen should be used instead of aspirin or ibuprofen. Acetaminophen with codeine or with oxycodone is sometimes given to pregnant patients, but only when absolutely necessary.
    - b. Sulfa antibiotics, such as trimethoprim-sulfamethoxazole (e.g., Bactrim®), tetracycline antibiotics, including doxycycline, and quinolone antibiotics such as norfloxacin, ciprofloxacin, ofloxacin and temafloxacin, are not used. Penicillin, amoxicillin, and erythromycin are generally thought of as safe, but amoxicillin-clavulanate (Augmentin®) is not.
  3. **Wilderness delivery** of a newborn is unlikely. However, in a catastrophic disaster, it may be more likely. While this section does not teach you any skills not included in the childbirth sections of EMT and EMT-P classes, you should understand the principles of normal childbirth beyond the short time-frame taught in EMT classes. (However, we are not in any way teaching you how to perform routine deliveries. We will not teach you to perform internal uterine exams or to routinely perform episiotomies or to repair introital tears. However, they are part of routine obstetric care, and you should know about them, along with the complications if they are either omitted or performed improperly. Normal parts of the obstetrician's delivery routine include the following.
    - a. If it appears as though a perineal tear is imminent, the obstetrician makes a small, neat **episiotomy** incision. This helps avoid a ragged tear that may lead to continued bleeding or infection.
    - b. If the placenta does not deliver promptly, the obstetrician applies gentle traction to the cord and firmly massages the uterus through the abdominal wall.
    - c. Once the placenta delivers, the obstetrician examines the placenta for completeness. If part is missing, the obstetrician uses a sterile gloved hand to explore the uterine cavity. The obstetrician then removes any retained material than might make bleeding continue.
    - d. The obstetrician then sutures any tears or episiotomies.
  4. If a pregnant woman begins to have vaginal bleeding, with or without cramping, it is called a **threatened abortion** (abortion in the medical sense, that is, a spontaneous miscarriage). There is no specific treatment except for bed rest. A pregnant team member with bleeding should be evacuated but without haste. If the bleeding is severe, start standard treatment for shock. Save any clots or tissue that she passes.
- 

### **J. Wounds: General**

1. You will be presented with a great variety of soft tissue wounds, ranging from massive disfiguring injuries to almost-microscopic splinters. Some can be dealt with definitively on the spot (e.g., small splinters), and others will require immediate first aid treatment and evacuation. (Control of bleeding is discussed in the section on *Assessment*.)

---

\* Vaginal bleeding is discussed in the section on *Wilderness Surgical Problems*.

---

## K. Wound Healing and Closure

1. When **evaluating a wound for possible closure**, you must bear two conflicting principles in mind and balance them carefully.<sup>10</sup>
  - a. The first principle is that wounds should be repaired. Why? Because they heal better that way, with less scarring, and have less limitation of function when healed. Also, especially in a wilderness setting, a closed wound is less susceptible to outside contamination.
  - b. However, a second principle is that wounds should be left open. Why? Because sealing a wound with sutures (or other closures) may mean sealing an infection in the wound, too. This converts an open, draining wound into an abscess. And, we know that abscesses do not heal unless they are opened and allowed to drain. Not only that, but certain **anaerobic** infections (e.g., tetanus, gas gangrene) are much more likely in a wound that is closed.
2. Soft tissue wounds heal in two main ways: by "**primary intention**" or by "**secondary intention**."
  - a. Wounds that are small, or that are surgically closed, heal by primary intention, usually with minimal scarring. New skin grows over the cut with little difficulty. If you staple or suture a wound closed, it will usually heal by primary intention.
  - b. Wounds that are left open heal by secondary intention, also called "by granulation," because the new flesh that fills in the gap looks granular and is thus called granulation tissue. Letting wounds "granulate in" is a reasonable approach for some wounds. Wounds take much longer to heal by secondary intention and it leaves large scars. Sometimes, the area can later be surgically repaired to decrease the size of the scar.
3. **Wounds that would benefit from surgical repair** can be managed in a variety of ways.
  - a. There is a "golden six (or eight) hours" in which to accomplish **primary closure** of a wound. Wounds that are older than 6-8 hours are at higher risk for developing a deep infection if closed. Thus these wounds are usually left open and treated as a high-risk wound. This is tempered by the area and nature of the wound: "clean" (as opposed to ragged) lacerations are less likely to become infected if closed, and areas with high blood supply (e.g., the face and scalp) are much less likely to become infected than areas with less blood supply (e.g., the foot and the shin).
  - b. Primary closure is the standard method for treating most low-risk wounds in the Emergency Department. However, there is no urgency to perform a primary closure in the wilderness. Why? Because wounds may be closed at about 4 days by **delayed primary closure**. Dr. Richard F. Edlich, a plastic surgeon and long-time director of emergency services at the University of Virginia, points out that "the fundamental basis for delayed primary closure is that the healing wound gradually gains sufficient resistance to infection to permit an uncomplicated closure."<sup>11</sup> In other words, you can close the wound in the first 6-8 hours, or you can wait 4 days, but you can't close most wounds in between. Delayed primary closure is still slightly controversial, but is our recommendation at the present.
  - c. Primary closure of wounds with suturing in the wilderness is not unreasonable. That is, it's reasonable if the person doing the suturing is experienced and has appropriate equipment

at hand, with adequate lighting. Wilderness EMTs, however, do not have the training, experience, or equipment to do so.

- d. You may, however, close some low-risk (see below) clean, non-ragged, superficial lacerations using some sterile tape strips and tincture of benzoin, after irrigation (see below). If, however, a person has not had tetanus immunization within 10 years, lacerations should **not** be closed in the wilderness because of the danger of tetanus.
- 4. An important distinction in open wounds is to separate wounds into **low risk** and **high risk** types (risk, in this case, meaning risk of serious complications). (This is different from the "high-risk"/"low-risk" classification as far as risk of tetanus as described in the *Wilderness Medical Problems* section.) High-risk wounds include:
  - a. open fractures or wounds with possible bone or tendon exposure;
  - b. bites or other saliva-contaminated wounds (e.g., "skinned knuckles" from hitting another person's teeth);
  - c. puncture wounds that are more than superficial; and
  - d. any wound that is grossly contaminated or in which there is massive crushing of tissues.
- 5. **High-risk wounds** are an indication for immediate evacuation. Control bleeding, and irrigate the wound (see below) unless it bleeds a lot. Leave the wound open, to drain as needed. "Close" it against external contamination by pack-

ing or covering with gauze or clean cloth soaked with a 1% povidone-iodine (e.g., Betadine®) solution (one part of the standard 10% povidone-iodine solution and nine parts of irrigation-quality water). Change the dressings (or at least apply more 1% povidone-iodine ) several times a day. You must protect the wound from contamination with good bandages. Most wilderness physicians recommend that, for such wounds, you should give an antibiotic if available.

- 6. **Low-risk wounds** are further divided into wounds that require surgical repair and those that do not. You should treat wounds such as superficial abrasions and very small cuts as follows (assuming that there is no significant bleeding).
  - a. Clean off any foreign material or blood with some drinking water (sterile water is not needed).
  - b. Apply a small amount of antibiotic ointment (e.g., bacitracin).
  - c. Apply an adhesive dressing (e.g., Band-Aid™) or other dressing and bandage.
  - d. Clean twice daily with drinking water and reapply ointment and dressing, until healed.
  - e. "Artificial skin" dressings such as Op-Site® and TegaDerm® look like large pieces of "stretchy" Scotch™ tape. They are excellent wilderness dressings for abrasions and lacerations because they are waterproof and bacteria-proof. However, they are water-vapor permeable, much like Gore-Tex™, and thus keep the wound moist though not waterlogged. These dressings should be applied with some tincture of benzoin to help keep it attached; this dressing should be left in

---

\* We do not plan to teach WEMT's to suture wounds as part of the standard course. However, tacking gaping wounds together with a few stitches of absorbable suture might be an appropriate skill for an add-on module for disaster WEMT's. (In a Third World disaster setting, delayed repair might be an economic impossibility for disaster victims.) We will leave such decisions to those creating add-on modules for the course.

*place for several days to a week, unless the wound appears to be infected. It is normal for a small amount of cloudy fluid to develop under the dressing; it is this moist environment that encourages cells to migrate out of hair follicles and sweat glands and repopulate the abraded skin surface. A certain amount of redness under the dressing is also a normal part of the healing process. If, however, the wound becomes very red with a large amount of frankly purulent fluid under it, the wound has become infected and the "artificial skin" is best removed to convert a "closed abrasion" to an open one. A large piece of OpSite™ makes an excellent protective inner bandage for large high-risk wounds, especially when the patient will be exposed to water and mud, as in many cave rescues.*

7. Unless impossible due to bleeding or the age of the wound, you should irrigate all wounds to remove bacteria.
  - a. Fluid for irrigation need not be sterile, but it should not have bacteria or spores of bacteria that tend to cause wound infections. Thus, water from a micropore filter with sufficiently small pores (e.g., the Katadyn® filter), though it might have viruses that could cause gastroenteritis if you drink it, will not have any pathogenic bacteria or spores, and is an ideal wound irrigant.
  - b. Water that has been treated with a standard iodine purification method should be acceptable for irrigation.
  - c. If you use boiling to purify water, boil the water for 10 minutes (to prepare water for drinking you need only bring water to a boil). (See the section on *The Wilderness Environment* for more about water purification.)
  - d. One common (and slightly morbid) question from WEMT students is whether urine is acceptable as irrigation fluid. In general, no. Female urine has too many bacteria to be effective. Male urine seldom has many bacteria, and might be used if absolutely necessary (e.g., a grossly contaminated

wound). However, the pressure of normal urination is insufficient for proper irrigation. (We would like a report from anyone who has used this technique.)

- e. To remove bacteria, you must direct irrigation water in a narrow, relatively high-pressure stream at the wound. Simply pouring water over a wound does little to remove bacteria. The pressure from a 35cc syringe with an 18 gauge needle or plastic IV catheter is ideal. This may be approximated by poking a small hole in a Ziploc™ or similar bag full of irrigating water and squeezing it. How much water should you use to irrigate? It depends on the size, location, and "risk" of the wound, and the amount of contamination. Although quality of irrigation is more important than quantity, one widely-used rule is to use 100cc of well-aimed irrigation fluid for every inch of wound, and more for contaminated or deep wounds.
- f. For grossly contaminated wounds, the irrigation fluid should be 1% povidone-iodine (e.g., Betadine®): 1 part povidone-iodine 10% solution and 9 parts water. Povidone-iodine is relatively nontoxic to wounds, but only "relatively" so; it is still more damaging to tissue than plain water or saline. Therefore, non-contaminated wounds should **not** be irrigated with povidone-iodine. Stream water may be mixed with povidone-iodine in these proportions and left for 30-60 minutes to ensure disinfection of the water.
- g. After irrigation, bleeding may start up again. Apply direct pressure again for a few minutes to stop any bleeding. Then, pack the wound with gauze soaked in 1% povidone-iodine, apply a self-adherent dressing (e.g., a Band-Aid™), or close with tape strips, as appropriate.

---

**L. Wound Care and Infections****1. Wound infections**

a. The likelihood that a wound contaminated with bacteria (and all wounds have at least a few bacteria) will become infected depends on:

- (1) the virulence of the bacteria;
- (2) the number of bacteria introduced; and
- (3) the resistance of the tissue against infection.

b. Pathogenic bacteria are introduced into wounds

- (1) in soil, saliva, or other contaminants, at the time of injury;
- (2) by migration of nearby skin bacteria;
- (3) by someone speaking, sneezing, or coughing near wound;
- (4) from the skin (particularly under the fingernails) of those caring for the wound, either initially, or when changing dressings; or
- (5) by contamination from other sources, i.e., when dressings become wet, or become contaminated with urine or fecal material.

c. The most common source of bacteria that cause wound infections is from the examiner's mouth ("talking to the wound") or fingernails, or from the patient's own skin bacteria. Areas with bacteria enough to cause infection include the hairy scalp, forehead, axilla, perineum, foreskin of the penis, the vagina, the mouth, and the nails. In other areas, bacteria are sparse and not a significant source of infection.<sup>12</sup>

d. Factors that determine the resistance of a wound to infection include the following.

- (1) The blood supply affects the resistance to infection. Wounds on the shin are notorious for infection because of poor blood supply, whereas

face and scalp wounds rarely become infected.

- (2) Dead tissue in a wound contributes to the likelihood of infection (breeding grounds and food for bacteria), so most surgeons will trim away ("debride") tissue that is obviously dead.

- (3) Foreign material in a wound contributes to the chances of a wound infection. Virginia red clay in a wound is well-known to promote infection, because it interferes with the normal function of certain white blood cells. Sutures, though specifically designed to not promote wound infection, are still foreign bodies and do promote infection to a significant extent.

- (4) Closing a wound may prevent normal drainage, an important normal defense mechanism. Sometimes, surgeons will close wounds but leave a small rubber **drain** in place to allow continued drainage.

- (5) Many "antiseptics," while they are good at killing bacteria and other pathogens, and while they are safe on intact skin, such as **around** a wound, are toxic to tissue in open wounds. Antiseptics should not be placed in wounds unless grossly contaminated; clean (not even necessarily sterile) water or saline, under pressure, is the approved way to clean bacteria from wounds prior to repair. (Even if repair is just approximating the wound edges with tape.)

- e. The main goal in caring for a wound is **not** simply to avoid infection, but to have it heal with function and appearance preserved as nearly as possible; that is why we "repair" wounds. Repairing a wound, however, can cause problems if one seals in an infection; drainage of pus (dead tissue, dead white cells, and bacteria) is an important defense mechanism.

**2. Guidelines for Preventing Wound Infections**

- a. Don't talk to wounds. They don't answer, but they **will** get infected. Wearing a mask isn't necessary, so long as you keep your mouth closed when pointing at the wound, and don't sneeze at it.
- b. Don't let your fingernail bacteria into the wound. Either scrub your nails thoroughly with regular soap (or surgical scrub soap if available), or better, wear sterile or clean exam gloves.
- c. Don't allow dressings to become wet; bacteria crawl much more quickly through wet dressings. (Wet dressings are sometimes used for certain conditions, but with care to avoid bacterial contamination.)
- d. For most healing wounds, clean once or twice daily with warm water to remove crust that serves as breeding ground for bacteria (particularly true for wounds that have been repaired). Then, apply a mild antibiotic ointment (e.g., Bacitracin ointment).
- e. Antiseptics such as povidone-iodine (e.g., Betadine®) may be used around but not in wounds. (Exceptions for high-risk wounds are discussed in previously in this section).

ture. The friction eventually causes the superficial skin to separate from a deeper layer of skin. This rupture occurs suddenly, producing moderate pain, commonly referred to as a "hot spot". In addition, the heat from the friction will often turn the skin red. Within two hours the blister cavity will fill with fluid.

- b. Prevention is easy and the method of choice. The feet should be clean and kept as dry as possible. Foot powder and/or antiperspirant on the foot help to keep it dry. A light inner sock of silk, nylon, or polypropylene will reduce moisture and friction on the skin. Some double-layer liner socks are now available. They are constructed with two layers that are designed to slide over one another, reducing friction on the skin. A heavy wool or artificial fiber outer sock and properly fitted boots are essential. If blisters are a chronic problem, the skin may be toughened with tincture of benzoin and talcum powder. Insoles and teflon sprays have also been found useful. Finally, it may be help to place moleskin on common trouble spots before starting to a field task. It may also be possible to get the boot "punched", that is, stretched at a trouble spot by a cobbler.

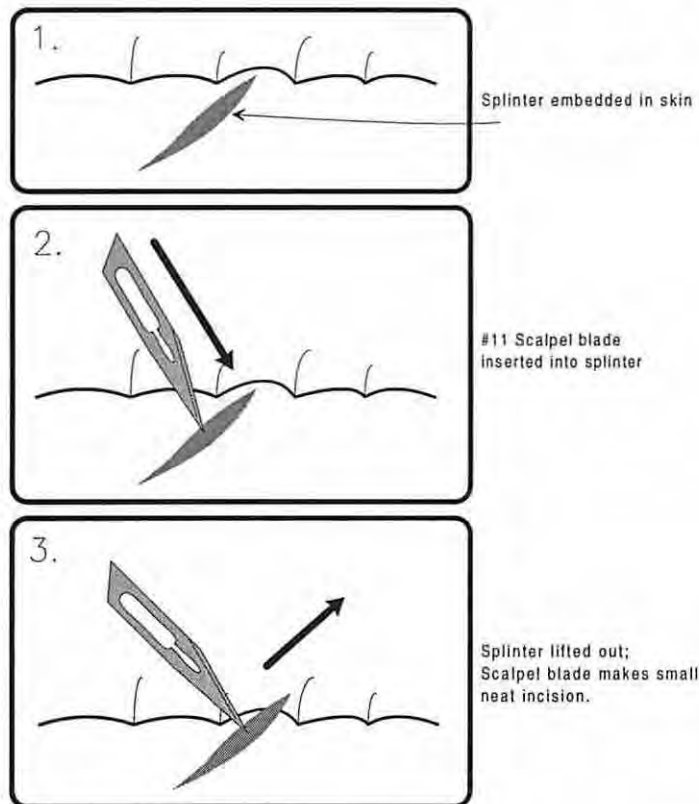
---

### M.Blisters

1. **Blisters** from friction are a common problem in wilderness travelers.

- a. Friction blisters are characterized by the separation of a tough superficial skin layer from a bottom layer with subsequent fluid buildup (infiltration). Friction blisters only occur where toughened or calloused skin is present, such as that on the hands or the feet. (Other parts of the skin simply abrade with friction.) Blisters are caused by friction creating a shearing force on the two bottom and top skin layers. Perspiration will cause an increase in friction because of the mois-

- c. If hot spots begin to develop, dry off the feet immediately, and apply moleskin to the affected area. If a blister has already formed, place a small piece of gauze over the roof of the blister before applying moleskin. Leave the blister intact unless it is in a place where it will obviously rupture (e.g., the sole of the foot). (Of course, almost all blisters occur in places that will likely cause them to rupture.) The blister top serves as an admirable sterile dressing for the raw skin underneath. You may make a small hole at the edge of the blister with a sterilized pin, needle, or #11 scalpel blade. Pressing gently will



**Figure 1.**  
**Removing a**  
**splinter.**

remove the fluid. Often, the blister top will then adhere to the bottom, forming a reasonable repair. If the top of the blister is partially ripped off, trim it away neatly; clean the area and cover it with some povidone-iodine ointment and a self-adhesive dressing (e.g., a Bandaid™) or other dressing. It is very important that SAR team members care for their blisters well, and keep them clean, since they are susceptible to infection, often leading to other complications.

### **N.Impaled Objects**

1. Splinters are a common minor medical problem. A little expertise in the use of a #11 scalpel blade to remove them almost painlessly will probably win you many admirers. The scalpel blade may be used to "stab" the splinter from the

side, and then to lift it gently out as shown. This will make a small, clean cut in the skin, but that is better than the ripping and smashing that often results from tweezers and needles.

2. Large impaled objects are a difficult problem in the wilderness. The standard for "street" EMTs is to leave large impaled objects in place and transport, using power tools to cut off long or fixed objects, and to stabilize during transport. Most impaled object cannot be "stabilized" during a wilderness evacuation, so you may need to remove an impaled object before transport. Whenever possible, you should discuss this with on-line medical command. When removing an impaled object, you should generally remove it slowly, and gently but firmly, pulling out along the line the object entered. You should stop your attempt if you encounter any sig-



nificant resistance or cause a significant increase in pain.

3. Fishhooks are a special case. The barbs make removing them backwards difficult. Sometimes you may be able to push the hook on through and clip off the barbed tip, allowing easy removal. When the tip is deeply embedded, it may be better to clip off most of the external part of the hook, and stabilize it in place for removal in the Emergency Department once the person reaches civilization.

## **Glossary**

- Anaerobic:** Generally used in reference to bacteria, indicating those species that can only grow (or grow much better) in an environment with little or no air, as in a puncture wound or a wound that is sutured shut. Important species include the bacteria that cause tetanus and gas gangrene.
- Atelectasis:** Collapse of small segments of lung.
- Avulse:** rip off.
- Benign:** As used in describing the physical exam of a body part: showing no evidence of abnormality.
- Blowout Fracture:** A fracture of the orbit around the eye, caused by an impact to the eye.
- Bradycardia:** Slow heart rate.
- Concussion:** After a blow to the head, a brief episode of unconsciousness or decreased neurological functioning with no detectable anatomic abnormality.
- Cricothyroid Membrane:** The membrane between the cricoid and thyroid cartilages of the larynx (voicebox). This thin membrane has little in the way of blood vessels and thus is a favored place for creating an emergency surgical airway.
- Cushing's Triad:** Tachypnea, hypertension, and bradycardia. Three signs of increasing intracranial pressure.
- Diplopia:** Double vision.
- Effusion:** Excess fluid.
- Epidural Bleeds:** Intracranial bleeds between the outer layer of the three meninges (the dura) and the skull.
- Hyperreflexia:** Increased activity of deep tendon reflexes ("DTR's").
- Hypertension:** High blood pressure.
- ICP:** IntraCranial Pressure. The pressure of the cerebrospinal fluid (CSF). Elevated when the brain is swollen, as from trauma.
- Intracerebral Bleeds:** Bleeding into the substance of the brain, either from trauma, from rupture of an aneurysm, or from a hemorrhagic stroke.

**Intracranial:** Inside the cranium (the skull).

**LeFort Fractures:** Fractures of the midface.

**Masseter:** The muscle responsible for chewing.

**Omentum:** Folds of fatty tissue attached to the intestines.

**Pallid:** white.

**Pursed-lip Breathing:** Holding the lips in a "whistling" manner while breathing out. This keeps some positive airway pressure in the lungs, and helps keep damaged alveoli and small airways from collapsing.

**Rebound Tenderness:** When performing an abdominal exam and gently palpating, you may sometimes find tenderness not only when you press in, but also when you let go. This is called rebound tenderness.

**Sacral Plexus:** The complex interconnection of nerves near the sacrum, where nerve roots exiting the lower spinal cord rearrange into the peripheral nerves of the lower part of the body.

**Septal Hematoma:** A blood clot under the mucosa of the middle of the nose.

**Sesamoid Bone:** A bone inside a tendon. There are small sesamoid bones in the tendons of the thumb and great toe, but the largest is the patella (kneecap).

**Subarachnoid Bleeds:** Intracranial bleeding into the cerebrospinal fluid surrounding the brain in the subarachnoid space.

**Subdural Bleeds:** Intracranial bleeding between the outer of the three meninges (the dura) and the middle layer (the arachnoid).

**Tachypnea:** Increased respiratory rate.

**Thoracic:** Chest.

**Threatened Abortion:** When a pregnant woman begins to have vaginal bleeding, with or without cramping.

**Tincture of Benzoin:** An alcohol-water solution containing a yellow-brown material that, when applied to the skin, allows adhesive tape to stick more tightly. It is similar in some ways to rubber cement.

**Upgoing Toes:** Refers to an abnormal Babinski test in an adult. Normally, the Babinski test (stroking the bottom of the foot with a fairly sharp object going toward the toes) will cause the big toe to reflexly bend down. When the toe is "upgoing" in an adult, you know that there is some abnormality in the brain or spinal cord.

**Zygoma:** The bone just behind the cheekbone.

**Zygomatic Arch:** The arch formed by the zygoma bone.

## **References**


1. Vandemark RM. Radiology of the cervical spine in trauma patients: Practice pitfalls and recommen-

## **Impaled Objects**

- dations for improving efficiency and communication. *AJR* 1990;155(3):465-72.
2. Freemyer B, Knopp R, Piche J, Wales L, Williams J. Comparison of five-view and three-view cervical spine series in the evaluation of patients with cervical trauma. *Ann Emerg Med* 1989;18(8):818-21.
  3. McNamara RM, Heine E, Esposito B. Cervical spine injury and radiography in alert, high-risk patients. *J Emerg Med* 1990;8(2):177-82.
  4. Bouma GJ, Muizelaar JP, Choi SC, Newlon PG, Young HF. Cerebral circulation and metabolism after severe traumatic brain injury: The elusive role of ischemia. *J Neurosurg* 1991;75:685-91.
  5. Quick G. A randomized clinical trial of rib belts for simple fractures. *Am J Emerg Med* 1990;8(4):277-81.
  6. Lazcano A, Dougherty J, Kruger M. Use of rib belts in acute rib fractures. *Am J Emerg Med* 1989;7(1):97-100.

## **Wilderness Surgical Problems - General**

7. Williams J, Kirkpatrick J. The nature of seat belt injuries. *J Trauma* 1971;11:207.
8. Kolowski J, Rost WB. Intra-abdominal injury from safety belts in auto accidents. *Arch Surg* 1956;73:970.
9. Ahmad W, Polk HC. Blunt abdominal trauma: A prospective study with selective peritoneal lavage. *Arch Surg* 1976;111:489.
10. Berk WA, Welch RD, Bock BF. Controversial issues in clinical management of the simple wound. *Ann Emerg Med* 1992;21(1):72-80.
11. Edlich RF, Thacker JG, Buchanan L, Rodeheaver GT. Modern concepts of treatment of traumatic wounds. *Adv Surg* 1979;13:169.
12. Lammers RL. Principles of wound management. *Clinical procedures in emergency medicine*. Philadelphia: Saunders, 1985:481.



Appalachian Search and Rescue Conference  
Center for Emergency Medicine of Western Pennsylvania

# Wilderness EMT Lesson Plan

## Part V-b: Wilderness Surgical Problems, Orthopedic

Draft Version 1.61, August 15, 1994

Comments to:

Brett D. Bender, M.D., Task Group V-b Leader

P.O. Box 370 Darby, MT 59829-0370

1-406-821-3104 (H) 1-406-363-2211 (W)

**Task Group:** Jeffrey S. Anderson, M.D.; Stuart M. Carpenter, EMT; John M. Chandler, M.D.; Sherwood Chetlin, M.D.; Keith Conover, M.D.; Bob Gedekoh, M.D.; Jody Gerard, M.D.; Carol Gilbert, M.D.; Elizabeth Honingford, M.D.; Robert Koester, EMT; Andrew Pietzman, M.D.; Richard A. Saunders, M.D.; Eric Weiss, M.D.; David M. Tauber, EMT-P; and Ricardo Townsend, M.D.

© 1989, 1994 by ASRC-CEM WEMCDP/WEMSI

This Draft contains material proprietary to the ASRC-CEM Wilderness EMS Institute; it is preliminary and may contain significant errors, so it should **not** serve as a reference. It may not be reproduced whole or in part without written permission. It is not to be circulated except to Staff and Consultants to the WEMSI, and students at our classes. However, a future draft version of this material **will** be made public.

**Project Coordinator:**

Keith Conover, M.D. 36 Robinhood Road  
Pittsburgh, PA 15220-3014 412-561-3413

## Verbose Outlines

We develop our WEMT Lesson Plans in a **verbose outline format** (what you see here). Why? Because the material is new to enough reviewers that the usual terse (“telegraphic”) lesson plan format might be incomprehensible or misleading.

Our Task Groups use these “verbose” outlines. Each part of the WEMT curriculum (about twenty in all) has a Task Group of five to twenty selected consultants. A Coordinator guides the Task Group in revising the section.

Each Task Group provides references to support its statements and for further reading. They also provide glossary entries for any new terms they introduce. (New, that is, to a reader with basic EMT and SAR training.)

Background material that should appear in the Textbook (see below), but instructors need not present in class, will appear *in a small, italic font*.

## Splitting the Outlines

When the outline satisfies the Task Group, it goes to our **Editorial Board**. This Board includes officers of the Appalachian Search and Rescue Conference and Center for Emergency Medicine of Western Pennsylvania, our two sponsors. It also includes experts in emergency medicine, search and rescue, and education. The Editorial Board reviews the verbose outline, and requests any necessary revisions. Once it is acceptable to the Board, we reformat the outline, into two distinct new versions.

We rewrite the material in the standard lesson plan format, which becomes a terse “telegraphic” outline. This version will be briefly reviewed by the Project Coordinator and then released to the public. It is the result of extensive review and testing, and will be used in all our classes. But, we still publish it as a draft, because we expect many good suggestions from the public. We distribute these drafts as widely as possible. After each year of public review, the Task Groups reviews comments, and submits revisions to the Editorial Board. Once all outlines have withstood a year of public scrutiny, we will prepare a single comprehensive curriculum with a Course Guide. We will continue to review and revise the curriculum regularly.

## On to a Textbook

As explained above, once the Editorial Board approves the verbose outline, we split it into two versions. Besides the terse teaching outline, it will also become the basis for a textbook chapter. The

Project Coordinator is the textbook Editor-in-Chief, and works closely with the Task Groups to consolidate and revise the verbose outlines into a comprehensive textbook. All who have contributed to the curriculum will be acknowledged as contributors. The textbook will be commercially published when completed. Until the textbook is available, we will distribute the verbose outlines or drafts of the textbook at classes.

## Notes: Wilderness Surgical Problems

This part of the curriculum is a condensed summary of surgical, as opposed to medical, problems. The criteria for including a problem are: (1) the problem is common in the wilderness and can be treated by a WEMT; (2) the problem is important to recognize, even if just to initiate the decision to abort the task and return to base, or to start an immediate evacuation; (3) management of the problem in the wilderness differs from that on the street; or (4) the problem might develop during a long evacuation.

The treatment for many surgical conditions involves the use of over-the-counter or prescription medications or minor surgical procedures. The choice of wilderness medical kit drugs and their use, and surgical procedures, is up to the WEMT’s medical director and appropriate state laws and regulations. However, medications are carried and used by most wilderness travelers, including search and rescue team members, and the WEMT, as the team medical expert, must understand proper use of these medications, and interactions and problems to expect from their use. The Pharmacology section summarizes this information, but specific surgical indications are covered here.

This section potentially overlaps with the sections on *General Medicine*, *Assessment*, *Wilderness Medical Problems*, and *Wilderness Trauma*. We have indicated where a topic is already covered in one of these sections.

Note that there are two Task Group Leaders for this section, and it is divided into V-a and V-b sections. Educational objectives 1-29 have been assigned to the general surgical section (V-a) and objectives 30-38 to the orthopedic section (V-b).

---

## **V. Wilderness Orthopedics**

---

### **A. Educational Objectives**

1. Differentiate these three kinds of neck injuries, as far as diagnosis, need for immobilization, and prognosis:
  - a. muscle strains;
  - b. bony injuries; and
  - c. neurological injury.
2. Explain how to estimate the approximate probability that a patient brought to an Emergency Department on a backboard, or a wilderness patient encountered by you, has a cervical fracture.
3. Outline your management of a patient with a potential cervical spine injury on the street, and in the wilderness; in particular:
  - a. outline the position of the Wilderness Medical Society; and
  - b. describe the role of "distracting" injuries in the physical examination of the cervical spine.
4. Outline the wilderness management of a patient with a pelvic fracture.
5. Describe the clinical signs and symptoms of lower back strains, evaluation of people with possible strains, and appropriate wilderness treatment.
6. Describe the mechanism of a herniated intervertebral disk, the signs and symptoms, and the wilderness management for a patient with a herniated disk.
7. Outline the examination and management of a team member who has developed back pain after lifting.
8. Define contusion, hematoma, and subungual hematoma, and outline the wilderness management of each.
9. Demonstrate the ability to:
  - a. trephine a subungual hematoma; and
  - b. remove an impacted ring using a piece of string.
10. Define "open fracture" in detail, and outline the proper management of open fractures in the wilderness.
11. Define: sprain, strain, contusion, fracture, dislocation, subluxation, and tendinitis.
12. Outline the principles of musculoskeletal examination of the extremities after trauma.
13. Outline standard musculoskeletal examinations of injured upper and lower extremities.
14. Outline the principles of management for traumatic extremity injuries including sprains, strains, and contusions.
15. Describe the causes, prevention, and treatment of tendinitis of the heel and of the wrist.
16. Outline the advantages, disadvantages, and risks of reducing dislocations in the wilderness, and list dislocations you should try to reduce when in the wilderness.
17. Outline the diagnosis and wilderness management of the following face and upper extremity injuries:
  - a. jaw dislocations;
  - b. finger and toe sprains, dislocations, and fractures, and "mallet finger" injuries;
  - c. hand fractures, including "boxer's fractures";
  - d. wrist fractures, including scaphoid fractures;
  - e. elbow injuries; and
  - f. clavicle fractures, AC joint sprains, rotator cuff tears, and shoulder dislocations.

18. Outline the diagnosis and wilderness management of the following lower extremity injuries:

- a. hip dislocations;
- b. knee injuries, including patellar dislocations and fractures, knee dislocations, and knee sprains and cartilage injuries;
- c. ankle sprains, dislocations, and fractures; and
- d. foot sprains and fractures.

---

### B. Disclaimer

**Recommendations for medical treatment in this curriculum are presented for training purposes only. We have attempted to ensure that all recommendations are consistent with current medical practices, but all care provided by WEMTs must be by the order of a physician. Your physician medical director must set protocols and standing orders, and you must follow them, even if they conflict with the recommendations in this curriculum.**

---

### C. Spinal Injuries

1. Neck injuries range from minor sprains to unstable fractures that may result in paralysis or death. We may divide non-penetrating neck injuries into three classes:

- a. **Muscular injury** (neck strain) is common after "whiplash" injuries, such as falls or motor vehicle accidents. Neck muscles that suffer a strain seldom hurt at first. Over the next hours to day, the muscles generally go into spasm, causing pain and limitation of motion. A history of **no** pain right after the injury, then spasm developing gradually over the next day or so, strongly suggests that the injury is limited to the muscles of the neck.

b. **Bony injury** ranges from tiny chip fractures or stable compression fractures, which present no danger of any injury to the spinal cord or spinal nerves, to fractures of the vertebral body with pieces of bone in the spinal canal, causing partial or complete paralysis. The reason EMT courses emphasize the need for spinal immobilization is not that unstable injuries are common, but that any damage to the spinal cord is irreversible: the cells in the spinal cord will not regenerate after injury.

c. **Neurological injury** to the cervical spine is usually but not always due to a bony injury. Direct trauma or severe "whiplash" may result in swelling or bruising of the cord itself without any bony injury. For instance, swelling in the center of the cervical cord causes the rare "central cord syndrome," with arm or hand tingling, numbness, or weakness, but with normal sensation and strength in the legs. Rupture of one of the neck ligaments, even without bony injury, may cause enough damage to the spinal cord to cause complete paralysis.

2. The medical literature indicates that the incidence of **unstable spine injuries** is small... the vast majority of trauma patients who arrive at an Emergency Department on a backboard have no spine injuries, stable or unstable.<sup>1</sup> Although there are a few reports of "painless" cervical spine injuries in alert, non-intoxicated patients, careful reviews and a recent study show no fractures in an alert patient with no severe "distracting" injuries (such as a femur fracture), with no tenderness on exam, and with a full range of cervical motion.<sup>2,3,4,5,6</sup>

3. **The rule for "street" EMTs and paramedics** is to make a decision about spinal immobilization based solely on the mechanism of injury. Thus, for the "street" EMT, anyone who has been involved in a significant fall, or who has

survived a violent airplane crash, should be immobilized. Other factors may make a street EMT immobilize a patient: for instance, a seemingly minor injury but with severe neck pain, or with neurological symptoms or findings on exam.

4. As a wilderness EMT, you will be confronted with many injured people who, in the city, would not enter the EMS system. (I.e., the person would not consider the injury severe enough to call an ambulance.) To avoid needless spinal immobilization and resulting complications to evacuation, you must use more specific guidelines than the "street" EMT in deciding when to apply spinal immobilization. You should use these special guidelines **only** when you are working in the wilderness; when in an urban or rural environment, you should be conservative and use the same rules as a "street" EMT.
5. The current (1989) Position Statements of the Wilderness Medical Society make the following recommendations regarding spinal immobilization in the wilderness (this is a paraphrase):
  - a. for EMT-Basics: as with "street" EMTs, decisions about spinal immobilization should be based on the mechanism of injury. Any of the following are indications for spinal immobilization:
    - (1) falls more than 15 feet,
    - (2) anyone who needs to be evacuated for a head injury, and
    - (3) high-velocity impacts (e.g., aircraft crashes, or motor vehicle accidents).
  - b. EMT-Basics confronted with a patient with a significant whiplash injury or any head trauma should immobilize the spine.
  - c. Advanced providers (we include in this Wilderness Command Physicians, orthopedic surgeons, neurosurgeons, emergency physicians, and Wilderness EMTs) may use the results of physical examination of the neck in their determination of whether to immobilize a patient who has not had a high-risk mechanism of injury. As a general rule, you do not need to immobilize patients who have had a head injury or high-velocity accident, but who:
    - (1) are alert and not intoxicated,
    - (2) have no neck pain or neurological symptoms,
    - (3) have no midline neck tenderness, and
    - (4) can move the neck through a full range of motion without pain ("FROM").
  - d. We would add to this Wilderness Medical Society policy the following:
    - (1) The patient must also be free of other major "distracting injuries." For example, an alert patient with a femur fracture may be distracted by the severe pain of the leg injury to not notice pain indicating a cervical spine fracture.
    - (2) The patient must not have **any** neck pain or tenderness, whether anterior, lateral, or posterior. One of our consultants has a yet-unpublished case of a patient with anterior neck pain and tenderness only, yet who had a significant bony cervical spine injury.
  - e. To examine the neck, you first palpate the midline firmly but gently with a finger or two, running your fingers from top to bottom. Start at the bottom of the skull, and move down until

---

\* Range Of Motion is often abbreviated in medical charts as ROM, and Full Range of Motion as FROM.

you reach the prominent posterior process of the first thoracic vertebra. Then, palpate the lateral neck muscles on either side. Finally, have a patient move the neck through a full range of motion: touch the chin to both shoulders, touch the chin to the chest, extend the head back, and then touch ears to the respective shoulders. A wilderness patient with no neck pain, no intoxication or decreased level of consciousness, no distracting injury, and who passes this exam, needs no cervical immobilization.

6. Here is a specific recommended protocol for "clearing the C-spine" clinically in the wilderness. **A person who has sustained a significant injury with the potential for cervical spine injury may be managed without cervical spine immobilization in the wilderness if and only if:**
  - a. **The person is alert and oriented, and not intoxicated; and**
  - b. **The person has no significantly painful "distracting injury"; and**
  - c. **The person has no complaints of neck pain or neurological symptoms; and**
  - d. **You can find no tenderness on examination of the neck, nor any abnormality on motor and sensory exam of the extremities; and**
  - e. **The person can demonstrate a full range of motion of the neck without pain.**<sup>7</sup>
7. A recent multi-center study shows that high doses of methylprednisolone (e.g., Solu-Medrol®) started in the first eight hours after spinal cord injury, and continued for 24 hours, improves outcome.

The experimental regime uses a constant infusion of methylprednisolone, which is impractical in the wilderness. However, an approximation is to give a single bolus of 2 grams, then 1 gram every 2 hours for the next 24 hours.<sup>\*8</sup>

#### D. Pelvic Fractures

1. Pelvic fractures in the wilderness are managed much the same as on the street: transport on a backboard. Even during only a short evacuation, an unpadded backboard turns into a torture device. This is never more true than for a patient with a pelvic fracture. Careful padding of the backboard, and careful packing of padding around the legs and torso, are a necessity. A rigid stretcher (e.g., a plastic basket litter) might in itself be an adequate substitute for a backboard, but standard wire basket (Stokes) litters will need the extra support of a backboard. For a patient with a pelvic fracture, a full-body vacuum splint is an ideal substitute for a backboard.
2. A standard part of Emergency Department management of a patient with a pelvic fracture includes a rectal examination. You, too, should perform a rectal examination on wilderness patients with pelvic fractures, checking for gross blood, and checking for (in men) a high-riding prostate gland. Report the results to your Wilderness Command Physician. You should generally place a Foley catheter in any patient with a pelvic fracture unless the prostate is high-riding.

\* The official recommendation is to give a bolus of 30 mg./kg. (about 2 one-gram vials for an average 70 kg. adult), then to give 5.4 mg./kg. per hour, which is 10.8 mg./kg. every two hours. For a 70 kg. adult, this would be roughly half of a 1-g vial every hour, or roughly a full 1-g vial every 2 hours.



---

## E. Back Injuries

### 1. Back Strains

- a. Back strains are common among wilderness search and rescue team members. Reaching for a distant handhold, slipping on a muddy or icy trail, and hoisting a litter with a 200-pound victim, are all ideally designed to rip and tear lower back muscles. Many of these injuries, if they happened at home, would not result in an ambulance call or even a visit to the doctor. But, since you're on the scene, you will be asked to "check out" many such injuries.
- b. The most common parts of the back to be injured are the lower (lumbosacral) paraspinal muscles. Usually, the person who strains the muscle is aware of a sudden pain or tearing sensation when it occurs. A feeling of a "pop" or "snap" is more suggestive of (but not diagnostic for) a herniated disk (see below).
- c. Many of the muscles in the lower back (and upper back, and neck) will develop spasm and increasing pain over about 12-24 hours after a strain. A common complaint is "I hurt my back yesterday, but I was able to finish the task. After a night on my Ensolite™ pad, now I can't move or straighten up at all." If you palpate the lower back muscles, you will find the ones in spasm feel more like bones than muscles; they are often tender. Having the person gently stand first on one foot and then the other normally will cause the back muscles to relax first on one side and then the other. Having the person walk while your thumbs are on the lumbar muscles should also allow you to feel relaxation with walking. A muscle that fails to relax is in spasm.
- d. The treatment of back strains has several parts.
  - (1) Very mild back strains need no particular treatment. Some aspirin and maybe a hot pack to the back at bedtime is all that is needed.
  - (2) More severe strains require strict bed (/foam pad) rest, flat on the back, for 1-2 days. Remember that most foam pads are not comfortable for extended periods; if you're putting someone on extended rest, find some extra pads for the patient. A pad or pillow under the knees helps straighten the lower back and helps relieve pain.
  - (3) Pain medications and muscle relaxants such as diazepam (e.g., Valium®) are standard treatment for bad back strains.
  - (4) After 1-3 days of bed rest, it is usually a good idea to start gently stretching out the back muscles. As with any form of stretching, the person should warm up the back muscles by walking, then do gentle passive stretching (i.e., no sudden jerks)

### 2. Herniated lumbar disks

- a. Between each vertebral body of the spine, there is an **intervertebral disk**. This disk is rubbery, and its compressibility provides much of the range of motion of our spine. The center of each disk is made of softer material than the outside. Aging or trauma may cause cracks in the outer part of the disk. The soft central disk material may herniate (push out) through the crack.
- b. By pushing on soft tissues, it causes localized pain and spasm of the nearby muscles. If there is no nerve compression (see below), there is no simple way to tell that this is a herniated disk rather than a back strain. However, such simple herniated disk is almost always treated with simple bed rest, so identifying this type of herniated disk in the wilderness is not very important.

- c. The herniated disk material may also press on a nerve leading out from the spinal cord. This may cause pain, numbness, tingling, weakness, or loss of deep tendon reflexes in the area supplied by the nerve. A common presentation is to have symptoms in half of one lower leg or half of one thigh. It is not important for you to know which nerves supply which areas. However, you should be able to do a standard lower extremity exam and note any abnormalities (see below). A person with such neurological symptoms may go on to have permanent damage to the affected nerves. Such a person should **not** carry a litter, and should **not** carry a heavy pack. If reasonably possible, the person should be carried out, but not urgently.
  - d. Rarely, a large bulging disk may push on the spinal cord itself. If the symptoms in the legs are widespread (as opposed to just one or two small areas), or if the person has problems urinating, you must suspect damage to the spinal cord. In such a case, you should treat the person as if he or she has a known lumbar fracture: immobilize the back and evacuate urgently.
  - e. If you think someone has a simple back strain you should say "It looks to me as though you have a simple back strain. However, there is always a small chance that you have a slipped disk or some other problem. If you develop numbness, tingling or pain in you legs, or any trouble passing your urine, you'll need to see a doctor or go to a local Emergency Department right away. If the pain doesn't go away soon, you should see a doctor, too."
- 3. Management of team members with back pain after lifting**
- a. You should use a standard approach to any team member who complains of back pain after lifting or twisting.
  - b. First, check to make sure the mechanism of injury is appropriate for you to evaluate as a likely back strain. For instance, **don't** use this protocol for someone who fell 35' onto his back and has severe back pain; he or she needs to be treated as a multiple trauma patient. This protocol is only for back pain after twisting or heavy lifting.
  - c. Next, ask two important questions:
    - (1) "Have you had any trouble passing your urine?" (If the injury just happened, the person doesn't know. But, if the injury happened several hours ago, and the person tried to go and couldn't, or is dribbling all the time, you want to know about it right away.)
    - (2) "Do you have any pain, numbness, tingling, or weakness going down your legs?"
  - d. Now, perform your standard exam for low back pain.
    - (1) Palpate the back just to either side of the midline. Press slowly but very firmly, to see if you can feel any spasm. If necessary, have the patient lift one leg or walk as described above.
    - (2) Press firmly over the sacroiliac joints (the dimples to either side of the sacrum). Tenderness here suggests a sacroiliac joint sprain, which is treated the same as a bad back muscle strain.
    - (3) Check sensation to pinprick between the first and second toes, and in both medial and lateral aspects of foot, ankle, lower leg, and thigh. Do this on both sides.
    - (4) Check motor strength in the lower leg (this can easily be done by having the person walk first on toes, and then on heels, with the toes up). Check motor strength in the thigh; this can be done by having the per-

- son try to flex and extend the knee against the resistance of your hand.
- (5) Check deep tendon reflexes in the knee and ankle. They should be about the same on both sides.
  - (6) Do a **straight-leg-raising test**. With the patient lying on his or her back, or sitting on a chair or equivalent, hold the thigh and knee both bent at 90°. Gently, without moving the back at all, straighten the knee. Markedly increased back pain, or increasing pain down the leg, is a positive straight leg raise test. What you are trying to do is to pull on the sciatic nerve. If it is tightly squeezed by a herniated disk or other problem, pulling on the nerve will irritate it and cause a positive test.
  - e. If the team member has a positive answer to either of the two questions, has any possibly positive findings on your lower extremity neurological exam, or has a positive straight leg raise, treat as a probably herniated disk. Otherwise, treat as a back strain.

---

### F. Closed Soft Tissue Trauma: General

1. **Bruises (contusions)** are caused by diffuse bleeding into the skin or other soft tissues. The treatment generally consists of the following.
  - a. **Elevate** the area as long as the area is swollen (the principle is simple: fluid, even the edema around an injury, flows downhill).
  - b. Apply **cold** for the first 24-48 hours to control pain, and to decrease swelling.
  - c. From 48 hours on, apply **warmth** to the area, to increase blood flow and speed healing.
  - d. An **elastic bandage** may help keep swelling down. Wrap it all the way to the tip of the extremity, but leave enough exposed so you can check capillary refill. This will help avoid a tourniquet effect and severe swelling beyond the elastic bandage. You must monitor the limb carefully to make sure that circulation is not cut off by the elastic bandage. Don't let anyone sleep with an elastic bandage on, because it might (unbeknownst) turn into a tourniquet overnight.
2. A **hematoma** is a localized collection of liquid or clotted blood, usually in the skin or muscle. Hematomas are treated the same as a bruise. However, if a hematoma is interfering with the person's ability to walk, and walking is the only practical means of evacuation: "the blood can be drained with a sterile needle and syringe following vigorous skin cleansing. A major closed soft tissue injury in proximity to a bone must be assumed to be associated with a fracture. These should not be drained." (From the Wilderness Medical Society Position Statement on wounds for EMT-Basics; note, though, that some hematomas, however, are clotted and cannot be removed this way.)<sup>9</sup>
3. A **subungual hematoma** is a collection of blood under a fingernail.
  - a. Subungual hematomas are exquisitely painful, and draining them offers marked relief. However, if the finger is fractured, this converts a closed fracture to an open one. Physicians generally drain subungual hematomas even if they are associated with an underlying fracture, but use scrupulously clean technique and start the patient on an oral antibiotic.
  - b. The best method for draining a subungual hematoma is to heat the sharp tip of a safety pin (or paper clip) to red-hot, then apply it firmly to the nail over the center of the hematoma. (The nail should be carefully cleansed first.) Sometimes, the safety pin must be reheated and used a second or third time to penetrate the nail. You should

take care to hold the safety pin with some heat-resistant material or a hemostat to avoid burns.

- c. An alternative is to use a #11 scalpel blade or a 18 gauge or similar size hollow needle with a twirling motion to drill through the nail. The pressure of this method, however, causes more pain than burning a hole with a hot safety pin.<sup>10</sup> It does have the advantage of not leaving black soot in the fingernail.
- 4. **Rings and bracelets** must be removed from any traumatized limb, to avoid a tourniquet effect brought on by swelling.
  - a. If a ring is difficult to remove secondary to swelling, try using some soap or other slimy material as a lubricant.
  - b. If necessary, a string may be used to help remove the ring. Slip a few inches of one end under the string. Wrap the string firmly around the finger just distal to the ring, so that the turns of string lie next to one another. Pull on the end of the string that goes under the ring; as the string unwinds, it will press out some of the edema fluid and slowly move the ring distally on the finger.<sup>11</sup>
  - c. If the ring cannot be removed with available equipment, all care must be taken to keep the digit well-elevated to prevent more swelling.

---

### **G.Principles of Wilderness Orthopedics**

#### **1. Definitions**

- a. (reserved)

#### **2. General Management of Orthopedic Injury**

- a. Start emergency evaluation and treatment of orthopedic injuries in the wilderness only after making an initial assessment of the whole patient. Orthopedic problems can wait until initial

treatment of major life-threatening injuries is complete and the patient's vital signs are stable.

- b. Your evaluation and treatment of an orthopedic injury in the wilderness is only initial "first aid." Immediately upon leaving the wilderness environment, arrange for definitive medical care at an emergency department or other appropriate medical facility.
- c. When you suspect an orthopedic injury, thoroughly examine the area that hurts. Examine the part of the injured extremity distal to injury, too: do a complete motor, sensory (nerve) and vascular exam. In most cases, you should examine the area proximal to the injury, too. After a traumatic injury, the patient may be aware of only the area of maximal pain, and may be distracted from other injuries distal or proximal to the site of maximal pain.
- d. **Documentation:** Complete, accurate and timely documentation is mandatory in the wilderness, even more so than on the street. Documentation is an important, critical part of medicine, and wilderness emergency medical services is no exception. The medical record you create for the patient must be an accurate and concise but complete record. Include:
  - (1) the history of the accident or illness;
  - (2) pertinent physical examination results;
  - (3) treatment administered;
  - (4) patient response to treatment;
  - (5) modification of treatment as indicated and condition during evacuation; and
  - (6) disposition at the definitive medical care facility.
- e. After your initial evaluation and treatment, you must regularly re-evaluate and continue (or modify) treatment as indicated. To document this care and condition during evacuation, add mul-

multiple progress notes to the medical record. Include in these progress notes pertinent physical examination results and any treatment modifications. Your medical record is successful and acceptable only if you create a picture in words. Someone who has never seen the patient should be able to completely understand and visualize the patient's accident and resulting injuries, the treatment you administered, any complications or treatment modification, and the patient's condition during the evacuation.

### 3. Sprains, Strains, and Contusions

- a. A **strain** is a tearing, overstretching or overexertion of a muscle. Unlike a sprain, no ligament or joint damage occurs during a muscle strain. The muscle fibers are partially torn apart, producing pain and sometimes swelling and ecchymosis of the local soft tissues. Sometimes a muscle is completely torn and the two parts of the muscle contract and ball up, causing a soft tissue deformity or bulging near the origin (proximal end) and insertion (distal end) of the muscle.

#### b. Sprains

- (1) A joint **sprain** occurs when it is twisted or stretched beyond its normal range of motion (ROM). As a result, some of the supporting capsule and ligaments are stretched, partially torn, or completely torn. A sprain is, in a sense, a partial dislocation. The bone ends are not completely displaced from one another by the force of injury, so they fall back into alignment when the force is released. Therefore, the severe deformity you see with a dislocated joint is not present with a sprain. Sprains vary in severity from a slight tearing to complete disruption of the supporting ligaments and capsule. Although sprains most often occur in the knee and ankle, any joint can be

sprained. The following are the signs of sprains: swelling, ecchymosis, tenderness, painful use of the joint, guarding and sometimes inability to use the joint secondary to pain.

- (2) The signs and symptoms of a sprain, a cartilage tear, and an intra-articular fracture are the same. Deciding which, and even ruling out very proximal and distal long bone fractures, is difficult even for experienced physicians. Often, this must wait until the physician evaluates the patient at a definitive care facility. Fortunately, the initial care of these injuries is identical, so specific diagnosis is not required for initial treatment in the field.

#### c. Contusions

- (1) (reserved)

### 4. Realignment of Long Bone Fractures

- a. In the wilderness, there are two indications for your realigning a deformed long bone fracture (including open fractures). They are:
  - (1) to correct or at least improve a sensory or vascular deficit secondary to the fracture, and
  - (2) to align severely deformed long bone fractures to allow splinting with adequate immobilization.
- b. Traction is the most effective way to realign a long bone shaft fracture. Excessive traction can be harmful. But when applied correctly, traction stabilizes the bone fragments and improves the overall alignment of the extremity. Don't try to reduce (set) the fracture or force all the bone fragments back into anatomic alignment. This is a physician's responsibility.
- c. Pull longitudinally, that is, along the normal axis of the injured extremity. Grasp the extremity distal to the fracture firmly. Once you apply traction, you will not release it until the limb is fully splinted. Have an assistant stabi-

lize by countertraction, holding the extremity proximal to the fracture. Use the least amount of force needed to align the extremity. Having a person support the injured extremity under the site of the fracture. This will make the patient more comfortable. Your initial pull will usually cause slight discomfort as the fragments move, but it quickly subsides. Then, you can apply further gentle but firm traction to align the fracture. If the patient strongly resists traction, or if it causes markedly increasing pain that continues, stop, and splint in the deformed position.

- d. Attempt realignment of a long bone fracture only twice, unless there is a sensory or vascular deficit. If you are unsuccessful after two attempts, or if you encounter resistance during realignment, splint the extremity as is. In these circumstances there is a greater risk of making the injury worse than the potential benefit of the realignment.

### 5. Splinting and Taping Techniques

- a. Without exception, you should perform a complete motor, sensory and vascular examination of the injured extremity before immobilization. If you find a nerve or vascular deficit, you will need to manipulate the injury to try to improve the outcome. Specific cases will be discussed in the text below.
- b. You should splint all fractures, dislocations and sprains before moving the patient, unless there is an immediate danger to the patient or yourself. Without exception, these injuries must be immobilized before starting the evacuation. Splinting prevents motion of fracture fragments, a dislocated joint, or damaged soft tissues. This reduces pain and makes evacuation easier on the patient. Splinting helps prevent the following:
  - (1) further damage of muscles, peripheral nerves and blood vessels from fractured bone ends
  - (2) laceration of the skin by fractured bone ends; and
  - (3) excessive bleeding of the tissues at the injury site.
- c. **Position of Function:** Your primary goal in splinting is to immobilize the appropriate part of the injured extremity securely in the position of function. (There are exceptions to splinting a specific joint in its position of function because of a special injury to that joint. These exceptions will be discussed in the text below.)
  - (1) The position of function of the joints of the upper extremities is as follows:
    - (a) finger (IP: interphalangeal) joints, both distal and proximal — extension;
    - (b) metacarpophalangeal (MCP) — 90° of flexion;
    - (c) wrist — 15° of extension;
    - (d) forearm — neutral position between pronation and supination;
    - (e) elbow — 90° of flexion
  - (2) The position of function of the joints of the lower extremity is as follows: the hip and knee extended and the ankle in neutral.
- d. If you cannot immobilize a specific joint in the position of function, then immobilize as close to the position of function as possible. Do not cause severely increasing pain, or push against a definite end point of solid mechanical resistance. The benefits of anatomic position are not sufficient to cause damage from excess force.
- e. For a suspected fracture of the shaft of any bone, make sure the splint immobilizes the joint above and joint below the fracture. With injuries in and around the joint, make sure the splint immobilizes the bone above and the

bone below the injured joint. Pad all rigid splints to prevent local pressure points. While applying the splint, use your hands to minimize movement of the limb and to support the injury site until the limb is completely splinted. When in doubt if an injury should be splinted, splint!

- f. After you apply any splint, always re-examine neurovascular status. Therefore, no matter what splint you apply, apply it so you can periodically assess the fingers or toes periodically for color, capillary refill, and sensation. You may not be able to test motor function, but you can test sensation. You can check two-point discrimination in the fingers and light touch and pinprick sensation distal to the splint. You can also assess capillary refill distal to the splint, especially in the nailbeds in the fingers and toes. Capillary refill should be two seconds or less. If you find a decrease in sensation, or capillary refill is more than two seconds, or if the patient complains of increased pain, numbness or tingling in the splinted extremity, resplint. Remove the splint and then reapply it slightly more loosely, but so that the injury is still appropriately immobilized. After reapplying the splint, recheck sensory and vascular status again. If it returns to normal, then recheck about every hour for several hours. Recheck sooner if the patient complains of a return of increasing pain, numbness or tingling.
- g. Although not always possible, you (or the patient) should elevate the injury, above the heart if possible above the heart. Apply cold. You may use portable cold packs, but you may also improvise by placing cold lake, river or stream water in a tightly sealed bag. Don't place cold packs directly on the skin or other exposed tissues. But placing a cold pack on an air splint or other thick, insulating material will not help.

Elevation and cold will (at least for the first 24-48 hours) help reduce swelling.

- h. You can fashion a splint from almost any material. It is simply a device to prevent motion of the injured part. However, you should have an adequate supply of standard commercial splints, including the SamSplint™ and wire-ladder splint. But if in the wilderness without a large medical kit, you may have to improvise. For fractures or dislocations about the shoulder, a commercially available sling and swathe, or an improvised triangular bandage, or simply using a safety pin to pin up the shirttail, will suffice.
- i. Air splints can adequately splint the upper extremity. Air splints generally provide adequate immobilization of tibia-fibula fractures or ankle fractures/dislocations. The advantage of air splints is that they are lightweight and compact. However, they become tighter and looser with changes in altitude, as from a helicopter flight, or from changes in temperature. You must monitor distal neurovascular status regularly.
- j. Vacuum splints are bags filled with many tiny plastic foam beads. When you pump out the air, it creates a vacuum inside, thus the name. The air pressure holds the beads solidly in whatever shape they were in when the air was pumped out. In a sense, these are the ideal splints for wilderness rescue: they are warm, comfortable, easily repaired with duct tape (unlike air splints), and even float. However, they are bulky when carried or when attached to an extremity. The best application is a whole-body vacuum splint in a litter. It serves as insulation under the patient, makes an excellent and comfortable backboard, and can splint extremity injuries, too.
- k. You can make strong, light, comfortable splints from plaster or "fiber-

glass.”\* “Fiberglass” is lighter and stronger than plaster. Apply over an adequate amount of cast padding, then wrap with an elastic bandage to hold it in place. Wait five or ten minutes for it to dry and harden. While drying in cold weather, keep them covered, to prevent frostbite.

- l. Wooden or metal splints, custom-made or improvised, will serve if other splint materials are not available. Securely affix the limb to the splint with tape, bandages, or elastic bandages.
- m. For femur fractures, the Kendrick Traction Device™ provides good traction. This splint is light and packaged for easy transportation. If you have no commercial splints, you may strap the injured leg to the non-injured leg, possibly with a tree limb or walking stick placed between them. If possible, transport the patient on a (padded) backboard.
- n. Air splints provide adequate immobilization of tibia-fibula fractures or ankle fractures/dislocations.

#### **o. Taping Technique:**

- (1) (reserved)

### **6. Dislocations and Subluxations**

- a. Dislocation of a joint occurs when the joint surfaces are completely displaced from one another. This only happens with severe injury to the supporting ligaments and joint capsule. Usually some of the supporting ligaments are completely ripped. The bone ends lock in the displaced position, making any attempt at motion of the joint difficult and painful. The most commonly dislocated joints are the fingers, shoulder, elbow, hip and knee.

The following signs and symptoms usually are seen the dislocated joint:

- (1) marked deformity of the joint;
- (2) swelling in the region of the joint;
- (3) pain at the joint that is aggravated by any attempt at movement;
- (4) virtually complete loss of normal joint motion; and
- (5) tenderness to palpation about the joint.

- b. In the wilderness, an indication for reduction of any dislocated joint is to correct or at least improve an associated sensory or vascular deficit. If there is a sensory deficit or no pulse distal to a dislocated joint, attempt reduction until the sensory deficit is relieved or at least partially relieved, or until the pulse has been completely or at least partially restored.

- c. You should routinely attempt to reduce certain dislocations when you encounter them in the wilderness: jaw dislocations, anterior shoulder dislocations, interphalangeal (IP) joint and metacarpophalangeal (MCP) joint dislocations of the hand, and interphalangeal (IP) joint and metatarsophalangeal (MTP) joint dislocations of the feet. As a general rule, only make two attempts at reducing these dislocations unless there is a neurovascular deficit. And, as with any dislocation, you should stop attempts at reduction if the patient complains of severely increased pain, or if you feel a solid mechanical blockage to continued movement. Why should you routinely reduce these dislocations? Because early reduction:

- (1) decreases pain, swelling, hemorrhage, muscle spasm;

---

\* Most of what we call “fiberglass” is really just polyester or similar material impregnated with a rapid-setting glue.



- (2) decreases chance or severity of nerve and vascular injury; and
- (3) decreases articular (joint) cartilage damage.
- d. Joints that have associated fractures or interposed soft tissue frequently will be unstable after reduction. In these cases, more care must be taken in applying the splint to prevent re-dislocation during splinting. The details of the reduction maneuver, including orientation of the pull, amount of necessary force, degree of patient sedation (if possible), and residual instability of the joint should be reported to the definitive care physician.
- e. As a general rule, the longer a dislocated joint remains dislocated, the harder it is to reduce. This is due to the muscle spasm that starts during the injury, and increases over time until reduction. Relaxation of muscle spasm is the key to successful reduction. Suggestion, guided imagery, or hypnosis may mean the difference between a successful or unsuccessful reduction. (See the section on **Principles of General Medicine** for explanation of these techniques.) If a physician is present at the scene or if medical control authorizes, premedication of the patient with a short-acting narcotic or benzodiazepine can be extremely helpful. However, you may not want to give long-lasting narcotic or sedative medications to a multiply injured patient. The short-acting IV narcotic fentanyl and the short-acting IV midazolam (Versed®) last for so short a time, though, that they might even be used in a multiply-injured patient to help reduction.
- f. For reduction of any joint dislocation, the goal of traction is to gradually fa-

tigue the muscle spasm around the dislocated joint. You must apply traction gradually, steadily, and constantly. Abrupt traction is very painful and will increase muscle spasm, further increasing pain. Pain from sudden traction will also make the patient resist your traction, and further tenses the muscles that the traction is supposed to fatigue. If you will be using a weight for traction (such as an arm), support the weight and then let it down carefully. So, apply traction gradually. It is important to convince the patient to relax the muscles and not resist traction. If you relax traction, even for a second, the muscles will spasm again, sometimes more than before you started the traction.

- g. After successful reduction, assess stability of the involved joint by a careful, controlled range of motion (ROM). Immobilize the joint before evacuation.

h. Subluxations:

- (1) (reserved)

**7. Open Fractures**

- a. Open fractures deserve special consideration. You must arrange immediate evacuation for any patient with an open fracture. These fractures require irrigation, debridement, and open surgical reduction in the operating room. You must assume that any fracture (or suspected fracture) with a nearby laceration or wound is an open fracture. Care of open fractures in the wilderness environment depends upon evacuation time. If you estimate that you can complete evacuation within six hours, give broad spectrum antibiotics as soon as possible (for example, ceftriaxone 2 gm IM or IV).<sup>\*</sup> Limit cleansing to just brushing off dirt and

---

<sup>\*</sup> If you have only oral antibiotic, a one-gram dose of amoxicillin-clavulante (e.g., Augmentin®),

other contaminants with clean gauze or a cloth and apply a dry, sterile dressing. Control hemorrhage by a carefully applying a pressure dressing and immobilize the extremity by splinting. Most orthopedic surgeons prefer to see the wound in its original condition. And, the orthopedic surgeon will meticulously clean and irrigate the open fracture in the sterile environment of the operating room. Therefore, if evacuation time is under six hours, there is not need for extensive cleaning.

- b. If evacuation time will exceed six hours, you should clean the wound, perform limited debridement (trim away any obviously dead tissue), and irrigate before applying a sterile dressing. Control hemorrhage with a pressure dressing, and immobilize. If you find evidence of any nerve or vascular, and the extremity is deformed, realign the fracture and reevaluate before splinting and evacuating.

### 8. Compartment Syndromes \*

- a. A compartment syndrome exists when locally increased tissue pressure compromises local circulation and muscular function. In the wilderness environment, compartment syndromes most frequently occur in association with fractures or severe contusions. This syndrome can occur also if a victim has been lying for some time across a limb with his body weight occluding the arterial supply. Elevated local tissue pressures may result from acute hemorrhage and leakage from capillaries, and when perfusion returns following ischemia.
- b. Although compartment syndromes have been described in the thigh, hand, foot and gluteal

(buttocks) regions, the lower leg and forearm are the most common sites. The lower leg and forearm are the most common sites because tight fasciae (sheets of tough tissue) surround the muscle compartments in these regions and also because these areas are involved frequently with fractures or severe contusions.

- c. The conscious patient complains of severe pain that appears to be out of proportion to the injury. The involved muscle compartment feels extremely tight, and applied pressure increases the pain. Stretching the muscles within the compartment produces severe pain. The cooperative patient notes decreased sensation to light touch and pin prick testing in the areas innervated by the nerve(s) traversing the affected compartment. Note that the most reliable signs of a compartment syndrome are pain, tight compartments, decreased distal sensation, and pain on passive stretch. Distal pulselessness, pallor, and slowed capillary refill may never be observed, even in the most severe compartment syndrome.
- d. When a compartment syndrome is suspected, emergency evacuation must be accomplished. The victim must be definitively treated in the first six hours after onset to optimize return of function to the extremity. An untreated compartment syndrome can produce severe nerve and muscle death within eight hours of onset.

### 9. Amputations

- a. Amputation victims require immediate evacuation.
- (1) Control hemorrhage by direct pressure. You will virtually never need a tourniquet except for extreme circumstances such as proximal extremity amputations.

---

cephalexin (e.g., Keflex®), or ciprofloxacin (Cipro®) would be a reasonable alternative, provided the patient can take PO medications. (See the section on *Principles of General Medicine* for more about the oral route in wilderness patients.) Erythromycin is so irritating to the stomach that, if it is the only antibiotic available, a reasonable maximum would be 500 mg. for a single dose. Higher doses would likely provoke vomiting.

\* Compartment syndrome is discussed in the section on *Wilderness Trauma*.

- (2) Without cooling, an amputated part remains viable for only four to six hours. With cooling, the amputated part may be viable for up to eighteen hours. Clean the amputated part with water or saline, wrap it in a moistened sterile gauze or towel, place it in a plastic bag, and transport it as cool as possible without freezing it. (Packing the bag in some snow is ideal.) Never place an amputated part in direct contact with ice or icy water. Keep the amputated part with the victim throughout the evacuation process. (It is not uncommon for the patient to arrive at the hospital with nobody knowing where the amputated part is.)

#### **10. Tendinitis**

- a. (reserved)

#### **11. The Evacuation Decision**

- a. The criteria for the decision to evacuate an orthopedically injured patient vary. They depend on the goals and immediate medical capabilities of the party or expedition. An expedition of explorers doing research in Antarctica with physician support, a field hospital at base camp, and adequate medical supplies and equipment will have very different criteria for evacuating an injured person than will a family spending a week hiking in the mountains, or a Field Team on a four-hour search task. In all cases, leaders should have a plan for contacting evacuation support teams should a serious injury occur.
- b. Musculoskeletal injuries that warrant immediate evacuation to a definitive care center include the following:
  - (1) if you suspect cervical, thoracic or lumbar spine injuries;
  - (2) if you suspect pelvic injury with posterior instability, significant suspected blood loss, or injury of the sacral plexus nerves;

- (3) any open fracture (open fractures require definitive medical care as soon as possible to prevent deep infection including osteomyelitis (bone infection));
- (4) if you suspect compartment syndrome;
- (5) joint dislocations involving the hip or knee (because of the associated risk of vascular injury or post-traumatic necrosis of the head of the femur);
- (6) patients with any injury where you suspect a nerve or vascular injury;
- (7) lacerations involving a tendon or nerve (you must evacuate to a facility where the appropriate type of surgeon is available: an orthopedic surgeon for most tendon or nerve injuries, and a hand surgeon for hand injuries); and
- (8) when treating individuals are not sure of the injury diagnosis or the injury's appropriate management.

#### **12. Standard Extremity Examinations**

##### **a. Principles of Orthopedic Examination**

- (1) Complete standard musculoskeletal examinations for the upper and lower extremities are presented here. These complete exams are not appropriate for all injured extremities. For example, if someone injured only the little finger, there is no need to examine all of the upper extremity. A detailed exam of the little finger plus a cursory exam of the rest of the upper extremity will detect any other accompanying injuries.
- (2) Your general rules for the parts of the complete extremity exam to do are as follows. Completely examine the injured extremity
  - (a) in all areas of pain, and all areas of obvious injury you can see; and
  - (b) from the most proximal pain or injury distal to the fingers or toes.

- (3) To identify any associated inconspicuous injury, do a cursory exam, including quick palpation and checking range of motion (ROM) of all joints, in the rest of the extremity.
  - (4) You can perform a complete exam only if the extremity is exposed. Therefore, undress the arm or leg before starting your exam. Remove clothing and gear without causing any more trauma. For a moderately or severely injured extremity, you may have to cut off clothing and gear. (You can always use some duct tape to put it back together if you must use the patient's own clothing for insulation and protection.) What about very severe environments? What if you see no indication to perform a complete exam of the entire extremity? In such cases, you may want to perform your cursory exam of the rest of the extremity through the patient's clothing. However, you must do so with the recognition that you may miss a severe contusion or laceration. If time and the environment allow, compare both arms or both legs. Humans are mostly bilaterally symmetric, and comparing may help you decide if an area is injured, especially if the patient is unconscious.
  - (5) Physical examination of the extremities is divided into four parts: circulatory function, nerve function, skeletal function and joint function. The next sections outline complete standard upper and lower extremity exams from these four aspects. Again, remember that these are **complete** examinations, and that you need not perform a complete exam on every part of every injured extremity.
- b. Circulatory Function**
- (1) Arteries and veins can be injured by blunt trauma, penetrating trauma, fractures, or dislocations.
  - (2) Palpate the following pulses in the upper extremities: the brachial, radial and ulnar arteries. Compare to the other extremity: pulses generally should be symmetrical. Assess temperature, color and capillary refill of the distal extremity and nailbeds. In a warm environment, The temperature should be warm, not cool or cold, and the color should be pink, not blue or pallid. Check the capillary refill in the nailbed of each digit: it should be less than two seconds (about the time needed to say "capillary refill").
  - (3) Palpate the following pulses in the lower extremities: the femoral, dorsalis pedis and posterior tibial arteries. Some people may not have both a dorsalis pedis pulse and posterior tibial pulse, but everyone has at least one of the two. (The popliteal pulse, behind the knee, is difficult to palpate even in a warm Emergency Department, so it is not usually worthwhile palpate for it in the field.) Assess temperature, color, and capillary refill.
  - (4) Remember that cool hands or toes may be normal when the patient is out in the cold or hypothermic. Compare the hands or toes of the injured extremity with the other hand or toes. When a person holds an injured extremity still, it will usually be cooler than the uninjured extremity from decreased muscle activity and therefore decreased blood flow.

**c. Nerve Function**

- (1) Nerve function may be difficult or impossible to evaluate in the unconscious or uncooperative patient. However, it is important to establish the status of peripheral nerve function in the extremity if circumstances and the environment allow. During evacuation, do repeated nerve function evaluations and compare to the

initial exam. A deteriorating nerve function will have important implications for definitive care of the patient, and may change your evacuation plans. Assess nerve function by checking sensory function and motor (muscle) function.

## (2) Sensation

- (a) Test sensation by two-point discrimination. Do this in all peripheral nerve distributions of the extremity. Two-point discrimination testing is better than light touch or pinprick testing, because it is the first sensory mode that is affected by decreasing nerve function from injury. Light touch or pinprick are acceptable for a cursory exam, but if you truly want to find evidence of nerve problems, especially in the hand, check two-point discrimination. To test for two-point discrimination, use a straightened and rebent paper clip or something similar. Move the two ends right next to one another. When pressed against the skin, the patient will be able to only feel one combined point. Gradually move the ends of the paper clip apart until the patient can feel both points. (Ask the patient to close his or her eye for this.) Compare against the opposite side, or against your own extremity. Test the following peripheral nerves for two-point discrimination:

- i) **Axillary Nerve**\*: test the proximal, lateral upper arm (over the deltoid muscle, also known as the "shoulder patch" area);
- ii) **Musculocutaneous Nerve**: test the lateral forearm;

iii) **Median Nerve**: test the volar (palmar) web space between the thumb and index finger;

iv) **Radial Nerve**: test the dorsal web space between the thumb and index finger; and

v) **Ulnar Nerve**: test the little finger.

- (b) If two-point discrimination is abnormal, specific area, then check light touch and pinprick sensation. Compare to the other extremity: they should be symmetrical.

## (3) Strength

- (a) Test motor function by checking the strength of each muscle group against resistance, then compare to the same muscles in the opposite extremity. Remember that pain may prevent a patient from showing full strength during this exam. Encourage the patient to demonstrate full strength or near-full strength, if for only a few seconds. Explain how important it is for you to test motor strength, and ask the patient to try to ignore the pain for a few seconds. Perform the following tests to evaluate muscle group strength in the upper extremity:

- i) Ask the patient to hold the arms out straight, in full extension (at a 90° angle from the long axis of the body). Push down on the distal forearms with your hands. If you can push the patient's injured arm down to his side, it indicates a strain of the deltoid muscle, or injury to the axillary nerve.
- ii) Ask the patient to flex the elbow to a 90° angle; try to extend the elbow by pulling on his distal forearm. If you can extend the elbow easily, it indicates a strain of the

---

\* We do not expect Wilderness EMTs to know the names of these nerves, only to be able to test the appropriate areas and report the results.

biceps muscle or injury to the musculocutaneous nerve.

- iii) Ask the patient to bring the thumb and **little** finger together in a circle (opposition). (Despite careful instruction, patients tend to place the thumb and index finger together in an "OK" sign. This is not true opposition and is not adequate for this test.) Place your finger inside the circle and pull out, trying to break the circle. Separation of the thumb and little finger indicates weakness of the muscles innervated by the median nerve, suggesting strain of those muscles or injury to the median nerve
- iv) Ask the patient to hold the wrist rigidly extended. Try to flex it with your hand. If you can flex it, it indicates a strain of the extensor muscles of the wrist or injury to the radial nerve
- v) Ask the patient to spread and hold all the fingers apart (abduct) strongly; you try to squeeze them together (adduct). If you can press the fingers together, it indicates a strain of the interosseous muscles or injury to the ulnar nerve.
- (b) To summarize: test motor strength in the upper extremity by pressing down on outstretched arms, by trying to pull the elbow straight, by trying to break a circle of the thumb and the **little** finger, and by trying to squeeze the outspread fingers together.
- (4) In the lower extremity, test sensory function by light touch and pin-prick in the all peripheral nerve distributions. (Two-point discrimination is poor in the lower extremities.) You can do a complete peripheral nerve exam by testing the lateral distal thigh, the lateral calf, the medial and lateral side and top and bottom of the foot, and the web space between the first and second toes.
- (5) *Each of the areas to be tested corresponds to a different peripheral nerve distribution:*
  - (a) *distal medial thigh (obturator nerve);*
  - (b) *proximal, lateral calf and posterior, lateral aspect of foot (sural nerve);*
  - (c) *distal, lateral calf and dorsum of the foot (superficial peroneal nerve);*
  - (d) *web space between great toe and second toe (deep peroneal nerve);*
  - (e) *instep of foot (saphenous nerve); and*
  - (f) *sole of the foot (tibial nerve).*
- (6) Test motor function of the lower extremity by examining the strength of each of the major muscle groups:
  - (a) **hip:** against the resistance of your hand, ask the patient to strongly flex, extend, abduct (away from the midline) and adduct (toward the midline);
  - (b) **knee:** against the resistance of your hand around the patient's calf, ask the patient to first strongly flex and then extend the knee against the resistance of your hand;
  - (c) **ankle:** against the resistance of your hand, ask the patient to strongly dorsiflex (pull the foot up), plantar flex (push the foot down), invert (as in trying to place the soles of both feet together) and evert the ankle;
  - (d) **toes:** against resistance of your hand, ask the patient to extend and flex (dorsiflex and plantar flex) the toes.

#### d. Skeletal Function

\* As with the upper extremity, we do not expect WEMTs to know the names of any of the nerves, only to be able to test them all for a complete exam.

- (1) Although bone ends protruding through the skin or gross deformity make it easy to diagnose a fracture, many fractures (particularly if nondisplaced) are less obvious. When the injury is near a joint, it is sometimes hard to tell a nondisplaced fracture from a sprain. If you suspect a moderate or severe sprain, you should also therefore suspect a nondisplaced fracture.
- (2) Inspect for possible signs of fracture: deformity, swelling, ecchymosis, exposed bone fragments, abrasions, lacerations, and hematomas. Palpate for signs of fracture: point tenderness and guarding (unwillingness to use the injured extremity).
- (3) To palpate the upper extremity, do so firmly, noting any signs of fracture or soft tissue injury. Use both hands.
  - (a) Examine the shoulder first and then proceed distally down the arm. Palpate the entire clavicle, acromio-clavicular joint, scapula, and humerus.
  - (b) At the elbow, specifically palpate the following bony landmarks:
    - i) the olecranon process of the ulna (the bony tip of the elbow);
    - ii) the epicondyles (the bony prominences on each side of the olecranon); and
    - iii) the head of the radius (deep under the muscle just distal to the lateral epicondyle).
  - (c) With the elbow fully extended, the epicondyles and the olecranon process normally form a straight, horizontal line. With the elbow flexed to a right angle (90°), they form an equilateral triangle. If you do not find these normal alignments, there is most likely a fracture or dislocation.
- (d) Next, palpate down the forearm to the wrist. At the wrist, palpate the distal radius and ulna, and the anatomic snuffbox where the scaphoid (or navicular) bone lies. (This is the small hollow at the base of the thumb metacarpal.)
- (e) Then palpate all five metacarpals of the hand and all 14 phalanges of the digits.
- (4) To palpate the lower extremity, palpate the hip (the femoral head is in the groin area), the femur, and then the tibia and fibula. Palpate for any swelling or effusion (excess joint fluid) of the knee. Palpate both medial and lateral knee joint lines, as well as the medial and lateral collateral ligaments (from just above to just below each joint line). Palpate the patella (kneecap). Next palpate both the medial and lateral malleoli of the ankle, as well as the calcaneus (heel) and the calcaneal tendon (Achilles tendon). Also palpate the ligament under the medial malleolus (deltoid ligament), and ligaments under the lateral malleolus (calcaneofibular, anterior talofibular and posterior talofibular ligaments).<sup>\*</sup> Next palpate the foot tarsal and metatarsal bones, specifically noting any tenderness over the base of the fifth metatarsal, which is the most commonly fractured bone in the foot. Then palpate the toes.
- (5) If you palpate an extremity and find no obvious signs of fracture, you should apply further tests looking for a fracture. Apply longitudinal and rotational forces distal to the area of suspected injury; in other words, push the ends of the long bone toward one another, then twist the bone. Note any pain, crepitus (grat-

---

<sup>\*</sup> We do not expect WEMTs to know the names of all of the ankle ligaments.

ing), or abnormal motion. If you find any, treat as a fracture. Do not use these tests on an obviously fractured bone: it will be painful and may even cause damage.

#### e. Joint Function

- (1) A complete exam of the injured extremity includes full active range of motion (ROM) of the joints. (Active ROM means the patient moves the joints, passive ROM means you move the patient's joints.) Ask the patient to demonstrate full active ROM of all joints of the upper extremity as follows:
  - (a) **shoulder:** arms over head (abduction), arms crossing in front and arms crossing in back;
  - (b) **elbow:** flexion and extension;
  - (c) **forearm:** pronation (rotate palm down) and supination (rotate palm up);
  - (d) **wrist:** flexion, extension, radial deviation and ulnar deviation;
  - (e) **digits:** flexion and extension of distal interphalangeal (DIP),\* proximal interphalangeal (PIP) and metacarpophalangeal (MCP) joints; check for rotational deformity by observing the orientation of the fingernails as the patient holds the DIP, PIP and MCP joints all flexed to 90° (almost a fist). The planes of the fingernails should be roughly parallel to one another and perpendicular to the orientation of the palm. (Compare to the patient's other hand; sometimes slight rotation is normal.) Then ask the patient to completely extend all the digits slowly, watching the digits for rotational deformity in the radial or ulnar direction. If

you see Rotational deformity, it suggests a fracture of the associated metacarpal. If a finger or thumb is injured, check for the following signs of a severe sprain:

- i) **Thumb:** check for stability of the radial and ulnar collateral ligaments of the metacarpophalangeal (MCP) and interphalangeal (IP) joints.\*\* Try to bend or "open" both the radial and ulnar sides of the joint by stabilizing the bone proximal to the joint with one hand. Then with the other hand, bend the distal bone in the ulnar direction when testing the radial side of the joint, and then in the radial direction when testing the ulnar side of the joint.
  - ii) **Fingers:** check for stability of the radial and ulnar collateral ligaments of the MCP, proximal interphalangeal joint (PIP) and distal interphalangeal joint (DIP); try to "open" each joint on both ulnar and radial sides.
- (2) When the lower extremity is injured, ask the patient to demonstrate active full ROM of all joints:
    - (a) **hip:** flexion, extension, abduction and adduction;
    - (b) **knee:** flexion and extension;
    - (c) **ankle:** dorsiflexion, plantar flexion, internal rotation and external rotation; and
    - (d) **toes:** flexion and extension.
  - (3) You can check ROM even in an unconscious or semi-conscious patient by performing passive ROM. ROM can be limited by pain or by mechanical obstruction. Do not push the ROM past any mechanical resis-

\* To remember which is the DIP and which is the PIP, you may wish to remember that the DIP joint is the first to go into the water when you DIP your hand into it.

\*\* The thumb has only two phalanges, thus only an IP joint, not a DIP or PIP joint.



tance, or if the patient shows signs of moderate or severe pain: you could cause further damage to an already injured joint.

---

## H. Jaw Dislocation

1. (reserved)
- 

## I. Hand and Finger (Phalanx) Orthopedic Problems

1. **General:** The fundamental concept for treatment of hand injuries is to preserve ROM and dexterity. These goals are attained by early splinting in the proper position for the specific injury. With few exceptions, this is in the standard "position of function" (see above).

### 2. Finger (Phalanx)

#### a. General

- (1) The diagnosis of finger sprains, subluxations, dislocations and fractures can be difficult in the field. Sprains, subluxations, dislocations, and fractures can have associated bone avulsion fractures, or disruption of collateral ligaments (sprains). You must anticipate these possible associated subtle but important, injuries when evaluating and treating finger injuries. Unlike simple dislocations, these injuries may require special attention to prevent problems in healing.
- (2) It is critical to understand the functional anatomy of the collateral ligaments and the volar plate. The volar plate is a tough ligamentous plate on the volar (palm) side of each finger joint. The collateral ligaments are the ligaments on either side of the joint. The collateral ligaments and volar plate are interconnected, forming a U-shaped hood around the lateral and volar aspects of each of the

MCP, PIP and DIP joints. These ligaments are taut when these joints are in flexion and they are lax when in extension. Therefore, you should splint these joints in flexion following an injury to the collateral ligaments to preserve maximum length of these ligaments and thus flexibility of the joint and dexterity.

- (3) Your examination of the finger must include inspection for deformity, swelling and ecchymosis of the injured bone or joint, as well as palpation for point tenderness, including along the course of a collateral ligament or volar plate (the joint capsule ligaments). Examine the injured joint for full ROM, and stress the radial and ulnar collateral ligaments for instability. Stress the joint in volar and dorsal planes (trying to move the two finger parts toward the palm and back of the hand respectively). Any instability should alert you to joint capsule, volar plate, or collateral ligament damage. Associated injury to adjacent nerves and blood vessels can also occur, resulting in compromise of sensation and blood supply. Therefore it is important for you to test two-point discrimination and capillary refill.

#### b. Finger Sprains

- (1) Sprains of the collateral ligaments can be first degree, second degree, or third degree. If the joint is stable to your exam but it is tender, swollen, or painful, the patient probably has a first-degree sprain. If you find minimal opening with a firm endpoint and moderate pain, it is probably a second-degree sprain. If you find significant opening (more than three to five millimeters) and severe pain, the patient probably has a complete (third degree) collateral ligament tear, and volar plate injury probably exists, too. (The MCP, PIP or DIP cannot open widely if the volar plate

is intact.) Isolated injuries to the volar plate are usually due to hyperextension, and can be partial or complete. An isolated volar plate injury would show as opening when you stress in a dorsal-volar direction as described above.

- (2) First degree sprains do not require splinting, unless for the patient's comfort while climbing. But, it is hard to rule out these subtle but very important associated injuries (volar plate injury, small intraarticular fractures). So, it is always a good idea to splint unless evacuation or life-threatening emergencies prohibit. You can use dynamic splinting ("buddy splinting" or "buddy-taping"): tape to an adjacent digit. This will provide increased stability and protection from a second sprain. When dynamic splinting fingers directly together, place a gauze pad or piece of cloth between the fingers to keep the adjacent skin from developing friction blisters. You can also leave the fingers a half-inch or so apart, and "bridge" the tape between them (place the sticky parts of the tape against one another between the fingers.) (You can do this just for the middle phalanx, or for all three.) This allows the sprained finger some extra mobility, but protects it from significant movement out of normal alignment. Such "bridge" or "figure-8" taping is particularly useful when the person must continue climbing.
- (3) If you find a second or third degree sprain or an isolated volar plate injury, splint. An aluminum finger splint (e.g., a small SamSplint™) is ideal for DIP or PIP injuries. The large SamSplint™ will work for a MCP injury. Place the splint on the dorsal (back) side. For all, splint in the position of function. You can also use dynamic splinting to the next finger for more stability.
  - (a) For first or second degree sprains of DIP or PIP joints, splint just the sprained joint.
  - (b) For third degree sprains and isolated volar plate sprains of the DIP or PIP joint, include the entire finger and MCP joint in your splint.
  - (c) For MCP sprains, splint the MCP and the PIP.
- (4) Third degree sprains and isolated volar plate injuries of the MCP joint must be immobilized by splinting with a volar splint or gutter splint from the end of the fingers to just distal of the elbow, with the arm, hand, and fingers in the position of function.
- (5) If the patient has a second or third degree sprain and you do not have a splint, "buddy-taping" with a piece of duct tape is better than nothing.

#### **c. Finger Dislocations**

- (1) PIP joint dislocations are the most common. DIP joint dislocations are less common, and MCP joint dislocations are the least common. These dislocations are sometimes open. They usually occur from a blow to the tip of the flexed digit (axial loading), or by hyperextension, or by crush injuries, or when the hand is entangled in a rope or another piece of equipment and twisted.
- (2) During a DIP dislocation, the distal phalanx usually dislocates dorsally or palmarly. During a PIP dislocation, the middle phalanx most commonly dislocates dorsally or palmarly. However, medial and lateral dislocations sometimes occur. Remember that some dislocations are associated with an intra-articular fracture. You should reduce DIP and PIP joint dislocations promptly. To reduce a DIP or PIP joint dislocation, hold the proximal phalanx and pull firmly along the axis of the digit distal to the dislocation. Hold the patient's hand

with the other hand. While still pulling firmly and constantly, slightly hyperextend the dislocation for dorsal dislocations (slight flexion for volar dislocations). Then, reposition the phalanx into its anatomic position. These dislocations are usually very easy to reduce. If there is significant resistance to your pull, or if you cannot reduce it in two attempts, stop. There is probably some soft tissue stuck in the joint, preventing closed reduction. In such a case, open reduction in the operating room is necessary. (These complex dislocations usually are irreducible because of interposition of the volar plate into the joint.)

- (3) Confirm successful reduction by putting the joint through a full range of passive motion. If you feel resistance, there is soft tissue interposition, and an open reduction is needed. If the dislocation is not reducible, or if there is soft tissue interposition, immobilize by splinting in the position of greatest comfort, without causing any sensory or vascular deficit. If possible, buddy tape the finger to the larger of the adjacent fingers.
- (4) Following successful reduction, test the collateral ligaments for injury. Also persuade the patient to show full active flexion and extension while you hold the other joints of the finger in extension. This isolates the motor and tendon function of the joint being tested.
- (5) A mallet finger injury may result from a DIP joint dislocation. If, after reduction, you find a mallet finger deformity, splint as for a mallet finger injury (see below).
- (6) *During dorsal PIP dislocations, the central slip of the extensor mechanism may rupture, forming a Boutonnière deformity (see below). If so, after reduction, immobilize in the position of*

*function, except that the PIP joint should be in full extension.*

- (7) Generally, dorsal MCP dislocations are easy to reduce. Flex the wrist as this position gives some slack to the flexor tendons. Then, hold the proximal phalanx, and pull along the axis of the digit while holding the patient's hand with the other hand. While holding traction, slightly hyperextend and reposition the proximal phalanx into its anatomic position. Volar dislocations frequently require surgical open reduction, especially those of the index finger. Try closed reduction anyway, especially if there is any neurovascular compromise. Attempt closed reduction the same maneuver as for the dorsal dislocation, except that while holding traction, slightly **flex** to reposition the phalanx into its anatomic position.
- (8) MCP joint dislocations usually are stable once you reduce them. Immediately after reduction, apply a dorsal splint over the middle and proximal phalanges and the metacarpal in the position of function. If you cannot reduce it, splint in the position of function and evacuate.
- (9) *Usually the proximal phalanx dislocates dorsally over the metacarpal head after the MCP volar plate is disrupted, but volar dislocations also occur. Sometimes there may be resulting soft tissue interposition, which blocks the reduction of the MCP joint dislocation. For example in dorsal MCP joint dislocations, the volar plate may become trapped in the joint, and/or the head of the metacarpal may be trapped by the volar soft tissues, including hand muscles and flexor tendons. Volar dislocations of the index finger MCP are notorious for this. Volar palmar dislocations may be irreducible because the head of the metacarpal becomes entrapped between the collateral ligaments. MCP dislocations may produce traction injuries to neurovascular structures, therefore prompt reduction is indicated. Re-*

*member it is important to check neurovascular status before and after reduction.*

**d. Finger Fractures**

- (1) The most common fracture of the distal phalanx is fracture of the distal tuft. It is often referred to as a "tuft fracture." If you find a painful subungual hematoma, you may drain it to decrease the amount of pain. But remember that draining a subungual hematoma over a distal tuft fracture makes a closed fracture an open fracture. The problem is that you can easily see a subungual hematoma, but cannot tell which subungual hematomas are associated with tuft fractures and which are not. Therefore, drain subungual hematomas as carefully and as antiseptically as possible. Also, start the patient on an appropriate antibiotic if available and if physician orders permit.
- (2) If you find a fracture or crush injury involving the nailbed, clean it well, and protect with a sterile dressing and protective splint. Place plenty of antibiotic ointment on the nailbed to prevent the dressing from sticking.
- (3) Fractures of the digital phalanges occur as a result of crush injuries, or when the digits are caught in ropes or within equipment being used to pull up objects. Angular or rotational deformity and crepitus may make these fractures obvious. Without X-rays, intra-articular fractures with subluxations or dislocations are difficult to tell from joint dislocations. Reduce these fracture-dislocations carefully and then splinted as for the a dislocation. If you cannot reduce the fracture-dislocation, splint with a volar splint or gutter splint from the end of the fingers to just distal of the elbow in the position of function.
- (4) Fractures of the metacarpal base, shaft and neck usually occur with crushing injuries or with axial loads

when rocks or other immovable objects are struck with the hand or fist. Metacarpal neck fractures occur most frequently in the fourth and fifth metacarpals and are frequently the result of a blow on the distal-dorsal aspect of the closed fist. Therefore they are sometimes referred to as a "Boxer's fracture." They are frequently associated with rotational deformity. When you find malalignment or significant shortening, attempt rotation and reduction with traction on the involved digit. Splint in the position of function. The patient may find it painful for you to try to get the MCP joint in a full 90° of flexion, but persevere and come as close as you can.

**e. Specific Finger Injuries****(1) Gamekeeper's Thumb**

- (a) The gamekeeper's thumb is a partial or complete tear (sometimes associated with an avulsion fracture) of the ulnar collateral ligament of the thumb MCP joint. When it is completely disrupted, the patient loses the "pincer" grasp of the thumb and index finger.
- (b) The term "Gamekeeper's thumb" originates because gamekeepers sometimes sustained tears of the thumb MCP joint ulnar collateral ligament as they wrung the neck of a game bird. The mechanism of injury is usually a fall on the outstretched hand that forcibly abducts the thumb at the MCP joint, for example when a person falls holding a ski pole. (When identifying the thumb MCP joint, remember the thumb has only two phalanges, and therefore only two joints: the MCP joint and interphalangeal joint (IP). The fingers have three phalanges.
- (c) You can make the diagnosis when you find point tenderness over the ulnar collateral ligament. Confirm

your diagnosis with the following stress test: stabilize the metacarpal of the thumb with one hand, and attempt to bend the proximal phalanx in the radial direction, with the MCP joint position in 10° to 20° of flexion, and then in full flexion. If there is a partial tear (sprain) of the ulnar collateral ligament, this will produce pain at the site of the ulnar collateral ligament. It is important for you to compare with the patient's uninjured thumb. If the radial deviation of the thumb on stress testing is 15° more than that of the patient's uninjured thumb, the ulnar collateral ligament is probably completely torn. The ulnar collateral ligament is much more commonly injured than the radial collateral ligament.

- (d) Immobilize a gamekeeper's thumb in a thumb spica splint. The thumb-spica splint is a short-arm splint from the end of the metacarpals to just distal of the elbow. It incorporates the wrist in 15° of extension, and the thumb in abduction. A gamekeeper's thumb is no reason for evacuation, but the person must see an orthopedic surgeon for re-evaluation within five days.

- (e) *Partial and complete tears of the radial collateral ligament of the thumb MCP joint also occur. The mechanism of injury is usually a fall on the outstretched hand which forcibly pushes the thumb toward the ulna at the MCP joint. Sprain of the radial collateral ligament can be made when the examiner observes point tenderness over the ulnar collateral ligament. The stress test described above with the following modification helps to confirm the diagnosis: attempt to deviate the proximal phalanx in the ulnar direction in the same two degrees of MCP flexion, instead of in the radial direction. If there is a partial tear (sprain) of the radial collateral ligament, this maneuver will produce pain at the site of the radial collateral ligament. If the*

*ulnar deviation of the thumb on stress testing is 15° greater than that of the patient's uninjured thumb, the radial collateral ligament is probably completely torn.*

## (2) Bennett's Fracture

- (a) *Bennett's fracture is an unstable, oblique intra-articular fracture of the ulnar base of the thumb metacarpal. It often occurs secondary to axial loading when an individual falls on the thumb with objects grasped between the index finger and thumb. This position is common when ski poles are grasped. These fractures are difficult to differentiate from ulnar collateral ligament injuries of the thumb MCP joint. When this fracture is suspected, the thumb and wrist should be immobilized in a thumb spica splint.*

## (3) Fifth Carpo-metacarpal Fracture-dislocation

- (a) *This fracture-dislocation is an intra-articular fracture of the palmar articular surface of the base of the fifth metacarpal that is unstable and therefore dislocates. It must be immobilized by splinting with a volar splint or gutter splint from the end of the fingers to just distal of the elbow with the DIP and PIP joints in 10 to 15° of flexion, the MCP joint in 50 to 90° of flexion, and the wrist in 15° of extension.*

## 3. Hand Lacerations and Tendon Injuries

### a. Hand Lacerations

- (1) When evaluating a hand laceration, find out the position of the hand at the time of injury, if you can. This will help you determine the most likely area a tendon may be injured. First note the resting position of the unsupported fingers. When a flexor tendon is completely cut, the unsupported finger rests in extension; and when an extensor tendon is completely cut, the unsupported finger rests in flexion. Then do a complete circulatory and neurologic exam. When inspecting a laceration with tendon involvement, observe the tendon through the laceration

during complete flexion and extension of the proximal and distal joints. If you don't do this, you may miss a tendon laceration. A tendon that is 90-percent lacerated can retain normal-appearing function on observation. Motion against resistance (strength testing) is usually noticeably reduced and sometimes painful. When examining for tendon injury, it is crucial to check for the presence of both tendon function and tendon strength against resistance.

- (2) When evaluating lacerations of the hand and fingers, remember that you must examine the function of each tendon separately. Hold all of the patient's other fingers extended, and have the patient flex the finger. This tests for flexion at the PIP. Next, hold the PIP straight and have the patient flex the DIP joint. Have the patient hold the hand in a fist, and extend one finger at a time. All should extend except the ring finger. (Because of the connections among the extensor tendons on the back of the hand, it is normally impossible to extend the ring finger MCP when the other MCPs are flexed.) Then, while holding the patient's finger, have the patient extend both the PIP and then the DIP against the resistance of your hand.
- (3) While evaluating a hand laceration, never use a hemostat to clamp a "bleeder." You may crush undamaged vital structures, such as nerve, tendon, or fragile blood vessel.
- (4) When dressing hand or wrist lacerations, use a bulky dressing for protection (padding) and splint in the position of function.
- (5) Tendon injuries occur secondary to blunt as well as penetrating trauma. For examples, the mallet finger, Boutonnière deformity and Swan-neck deformity are injuries of the fingers that usually occur from blunt trauma.

#### b. Specific Tendon Problems

- (1) **"Mallet Finger" Injuries:** The mallet finger is a flexion posture or "droop" of the finger at the DIP joint. It is from disruption of the extensor tendon at its attachment to the dorsal base of the distal phalanx. The insertion of the extensor tendon may be avulsed, or there may be a piece of bone still attached to the extensor tendon, and therefore an avulsion fracture. These injuries often are only minimally painful. There is complete passive but incomplete active extension of the DIP joint. The cause of the injury is usually a sudden blow to the tip of the extended finger. (A laceration over the dorsum of the distal joint may also sever the extensor tendon and result in a mallet finger deformity.) Always examine the PIP joint to rule out co-existing injury there. The mallet finger is an exception to the "position of function." Apply a dorsal splint over the middle and distal phalanges with the DIP joint in extension, or a few degrees of hyperextension, but no more than 5°. This splint should allow motion of the PIP joint, but prevents any motion of the DIP joint. Standard treatment is constant immobilization for six weeks. The patient should see an orthopedic surgeon during or at the end of this time. There is no need for evacuation or emergency department evaluation unless you find an

---

\* This also makes a good party trick, at least until the unsuspecting victim thinks to check other people's hands and finds out it's true of everyone else, too.

other associated injury. Mallet finger injuries associated with an avulsion fracture sometimes have to be repaired surgically.

- (2) **Boutonnière Deformity:** The Boutonnière deformity of the finger consists of flexion of the PIP joint and hyperextension of the DIP joint. The extensor tendon that extends the DIP joint consists of two lateral bands. These lateral bands are maintained on the dorsal surface of the finger, including the PIP joint, by the fibrous bands. When disruption of the extensor tendon insertion into the dorsal base of the middle phalanx occurs because of injury or disease, these fibrous bands may tear or progressively stretch, thus allowing the lateral bands of the DIP extensor tendon to slip volar on either side of the PIP joint. One lateral band slips to each side of the PIP joint. In their new position, the extensor tendon attached to the dorsal base of the distal phalanx still extends the DIP joint (usually in hyperextension), but now it will also **flex** the PIP joint, causing the characteristic boutonnière deformity. The deformity may not be present immediately following an injury. It can develop over several days or weeks as the lateral bands of the DIP extensor tendon drift progressively toward the palmar side of the finger. Treatment is surgical. Field treatment is to immobilize the PIP joint by dorsal splinting over the distal, middle and proximal phalanxes and the metacarpal of the injured digit with the DIP joint in 10 to 15° of flexion, the PIP joint in full extension, and the MCP joint in 50 to 90° of flexion.
- (3) **Swan-neck Deformity:** The Swan-neck deformity of the finger consists of the PIP joint in hyperextension with the DIP joint in flexion. It can be seen in a variety of conditions such as PIP joint volar plate injury, old mallet finger deformity, rheumatoid arthritis and certain types of spasticity. Definitive treatment is surgical. Field treatment is to splint the entire finger on the volar surface with the PIP and DIP joints in full extension.
- (4) **Rupture of the Flexor Profundus Tendon:** Occasionally, when an object is firmly grasped and then pulled away, rupture of the flexor profundus tendon may occur. The

*flexor profundus tendon inserts on the volar base of the distal phalanx and it is responsible for flexion of the DIP joint. On examination, active flexion of the DIP joint will be absent. This injury should be immobilized with a dorsal splint over the middle and distal phalanges with the DIP joint in 15° of flexion. This splint allows motion of the PIP joint, but prevents motion of the DIP joint.*

#### 4. Hand Infections

##### a. Paronychia

- (1) A paronychia is an infection of lateral nail fold (the soft tissue around the fingernail). It usually begins as a "hangnail." It can spread around the nail eponychium. It appears red and swollen, and is usually painful. There is sometimes purulent drainage around the margin of the nail. The most common infecting organisms are *Staphylococcus aureus* and *Streptococcus*.
- (2) This infection is easily treated by placing a No. 11 blade parallel to and alongside the top of the nail, elevating the epithelium along the lateral nail fold. This maneuver will drain the abscess. The patient should apply warm soaks for a few days until the infection resolves. Antibiotics are usually not necessary.

##### b. Human Bite Infections

- (1) Human bites to the hand are very serious and it can result in significant and permanent loss of function. They usually occur from the patient striking another person in the teeth during a fight. They common over the dorsum of the MCP joints. Because they are inflicted with the hand in a clenched fist they are therefore called clenched fist injuries. An important point is that the wound may appear benign initially, but is usually inoculated with a potent mixture of bacterial flora. The most common organisms are *alpha-* and *beta-hemolytic streptococcus*, *Staphylo-*

*coccus aureus, Eikenella corrodens, and Neisseria species.*

- (2) Human bite injuries require prompt treatment. Treatment should be initiated immediately with the administration of tetanus prophylaxis and intravenous antibiotics. If the extensor tendon is injured, surgical evaluation, debridement, drainage and copious irrigation is required. Extensor tendon repair is delayed for 5 days until the wound is clean and the skin wound is allowed to heal by secondary intention (without sutures). When inspecting for tendon injury, put the hand in the fist position in order to bring the tendon into the position it was in when the injury occurred.

#### c. Felon

- (1) A felon is a deep infection (abscess) of the pulp space of the fingertip. The patient complains of a marked, throbbing pain. The distal fingertip is swollen, red and extremely tender. As the pressure within the pulp space increases, perfusion is impaired, which can lead to pulp necrosis, osteomyelitis, a draining sinus or an even more serious hand infection. The most common organism is *Staphylococcus*.
- (2) This infection is best treated by draining the abscess. Drainage is best accomplished by making an anterolateral incision with a No. 11 blade, beginning 5 mm distal to the distal digital crease and extending into the pulp space. This anterolateral approach protects the neurovascular bundle. Warm soaks should be done for a few days until the infection resolves. Antibiotics are usually not necessary.

- d. **Web Space Infections:** Web space infections commonly occur following penetrating injuries in the web space between the digits. These patients present with dorsal and volar swelling of the web space, with separation of the digits. These infections must be treated promptly with tetanus prophylaxis, incision and drainage, copious irrigation and intravenous antibiotics.

#### e. Mid-palmar Space Infections

- (1) Mid-palmar space infections occur when the radial and ulnar bursa that extend into the palm of the hand become infected, either from extension of a flexor tenosynovitis or from a penetrating wound to the palm. A horseshoe configuration abscess is commonly found because 50 percent of patients have communication between the radial and ulnar bursa. These infections must be diagnosed promptly. Then prompt surgical incision, drainage and irrigation are required, as well as admission to the hospital for administration of intravenous antibiotics.

- f. **Flexor tenosynovitis:** Flexor tenosynovitis is diagnosed by the following signs: a flexed resting posture of the affected digit, symmetrical swelling of the finger, tenderness over the flexor tendon sheath, and pain upon passive extension. The most common organisms are *Staphylococcus aureus*, *Streptococcus* and *Pseudomonas*. Prompt surgical incision, drainage and irrigation are required, as well as admission to the hospital for administration of intravenous antibiotics.

---

## J. Wrist Orthopedic Problems

### 1. Wrist Sprains

- a. (reserved)

### 2. Wrist Dislocations

- a. Wrist (carpal) dislocations usually come from a fall onto the outstretched hand. Wrist dislocations are hard to distinguish from wrist fractures or fractures of the distal radius on exam alone. Also, wrist dislocations frequently are associated with wrist fractures.
- b. Lunate dislocations can occur dorsally or palmarly. Dorsal lunate dislocations are palpated easily over the mid-dorsum of the wrist. Volar lunate dislocations usually are not palpated.
- c. Perilunate dislocations occur when the rest of the carpal bones dislocate around the lunate. The lunate remains in its normal position of alignment with the radial head. However, the



*remainder of the carpal bones are dislocated dorsally or palmarly.*

- d. You should try to reduce wrist dislocations in the field. When checking neurovascular status, be especially careful to check the distribution of the median nerve. It is the nerve most often injured in any wrist injury. Reduce by grasping the hand in the handshake fashion; apply countertraction on the forearm with your other hand; and then pull traction. Significant force is required. Premedicate the patient with a short-acting narcotic or a benzodiazepine if you can. If you cannot reduce it after two attempts, or if you suspect a nerve or vascular injury evacuate as soon as possible. Immobilize the wrist with a volar short-arm splint from the end of the fingers to just distal of the elbow. Use the position of function.

### **3. Wrist Fractures**

- a. If you find pain and tenderness about the wrist with no significant deformity, considered it to be an intercarpal ligamentous disruption or a carpal fracture. Apply a volar short-arm splint.
- b. Wrist fractures occur from significant rotational forces or high axial loading forces, such as those occurring with a fall onto the outstretched hand. The patient complains of pain and later of swelling around the wrist. Any use of the hand or rotation of the forearm increases the pain. Many fractures of the carpals are associated with wrist dislocations. Reduce these suspected fracture-dislocations as described above.
- c. Precise diagnosis of fractures of the carpal bones is impossible without X-rays. The most common fracture is the scaphoid. (Another name for the scaphoid is "navicular.") Suspect this fracture when the area of maximum tenderness is in the anatomic snuffbox. The anatomic snuffbox is a small

"hollow" at the base of the thumb. It is just distal to the end of the radius on the radial side. You can confirm the likelihood of a scaphoid fracture by causing increasing pain when you axially compress the thumb against the scaphoid bone. If you suspect a scaphoid fracture, immobilize the wrist and thumb with a thumb-spica splint. The thumb-spica splint is a volar short-arm splint placed from the end of the metacarpals to just distal of the elbow that incorporates the wrist in 15° of extension and the thumb in abduction.

- d. *Lunate fractures are common also. This fracture is suspected when the patient's area of maximum tenderness is over the lunate fossa. The lunate fossa is located just distal to the rim of the radius, directly at the base of the long finger metacarpal. If this fracture is suspected, the wrist and thumb must be immobilized with a thumb-spica splint.*
- e. *Another common fracture is the hook of the hamate. This fracture frequently occurs when the hand is used to apply great force to an object with a handle on it, such as an ax or a hammer, and great resistance is encountered. This fracture is suspected when the patient's area of maximum tenderness is at the base of the hypothenar eminence (the volar-ulnar aspect of the wrist). If this fracture is suspected or if any other carpal injury is suspected, the wrist must be immobilized with a volar short-arm splint placed from the end of the fingers to just distal of the elbow with the DIP and PIP joints in 10 to 15° of flexion, the MCP joint in 50 to 90° of flexion, and the wrist in 15° of extension. Elevate the elbow and apply cold if possible.*

---

### **K. Forearm Fractures**

- 1. **Ulna shaft fractures** are usually associated with radial shaft fractures at the same level. When the ulna is fractured but not the radius, it is usually the result of a direct perpendicular blow (the "nightstick fracture"). Sometimes an

ulna shaft fracture is associated with a fracture or dislocation of the radial head.\* Therefore you should also examine the elbow carefully for deformity, swelling, or tenderness. The patient usually complains of severe pain in the forearm or the elbow that is worse with any movement of the elbow, forearm, wrist or hand. Apply a posterior long-arm splint to immobilize the fracture. It should extend from the proximal humerus to the end of the metacarpals, with the elbow in 90° of flexion, the forearm in neutral position, and the wrist in 15° of extension. Evacuate the patient for definitive care as soon as possible.

2. **Fractures of the proximal ulna (the olecranon)** occur as a result of a fall onto the posterior elbow, or by avulsion from a violent asymmetric contraction of the triceps. The patient complains of severe pain in the elbow that is worse with any movement of the elbow or distally. You will find maximal tenderness over the olecranon. The patient may be unable to actively extend the elbow against gravity if the triceps is detached from the olecranon. In cases of severe trauma, the olecranon fracture may be associated with an intra-articular fracture of the distal humerus. These fractures usually produce severe swelling of the elbow. Immediate evacuation of the patient is mandatory if the fracture is open, or if the fracture is associated with a nerve or vascular injury or severe swelling. Apply a posterior long-arm splint to immobilize the fracture. It should extend from the proximal humerus to the end of the metacarpals, with the elbow in 90° of flexion, the forearm in neutral position, and the wrist in 15° of extension. Evacuate

the patient for definitive care as soon as possible.

3. **Distal radius fracture** is generally from a fall onto the outstretched hand. These fractures are frequently associated with fractures of the distal ulna. The patient complains of severe pain around the distal forearm or the wrist that is worse with movement of the hand. There is usually obvious deformity. You can find the fracture by finding the area of maximum tenderness. Your neurovascular exam should concentrate on the median nerve and the radial and ulnar arteries. If you identify a nerve or vascular injury, try to reduce the fracture by applying traction and correcting the deformity. To reduce this fracture, have an assistant firmly grasp the forearm. Then you should apply slow and firm but strong longitudinal traction. You will need to "exaggerate" the fracture before the deformity is corrected. This is necessary because the periosteum (the membranous covering of the bone) is often still intact, and holds the bone ends "locked" out of place. (Exaggerate the dorsal distal radius fracture by bending the hand dorsally and then reduce the fracture by bringing the hand palmarly to correct the deformity. Exaggerate the volar distal radius fracture by bending the hand palmarly and then reduce the fracture by bringing the hand dorsally to correct the deformity.) Continue to hold the fracture, without letting go, while your assistant readies the splint and applies it. Use a short-arm anterior-posterior splint ("sugar tongs" splint) from the end of the metacarpals to just distal of the elbow with the wrist and forearm in neutral position. If you find no nerve or vascular injury, do not try to reduce the fracture; simply immobilize with the same "sugar tongs"

---

\* This specific fracture is called a Monteggia fracture.

splint. Evacuate promptly but not hastily.

- a. In the wilderness, radial shaft fractures will occur most commonly from a direct blow on the forearm, or from a fall with angular or axial loading of the forearm. Sometimes a radial shaft fracture is associated with a dislocation of the distal joint between the distal radius and the carpal bones, so examine the wrist carefully for deformity, swelling or tenderness. Radial shaft fractures commonly are associated with ulnar shaft fractures at the same level. The patient complains of severe pain in the forearm or the wrist that is worse with movement of the wrist or hand. With fracture of both the radius and the ulna, forearm instability can be significant. Apply a posterior long-arm splint to immobilize the fracture. It should extend from the proximal humerus to the end of the metacarpals, with the elbow in 90° of flexion, the forearm in neutral position, and the wrist in 15° of extension. Evacuate the patient for definitive care as soon as possible.

#### b. Radial Head Fracture

- (1) Fractures of the radial head usually occur from a fall on the outstretched hand. The patient complains of pain around the elbow that is exacerbated by pronation and supination of the forearm. Usually flexion and extension of the elbow causes less pain. The patient usually cannot show full extension of the elbow. You can locate the fracture by finding maximum tenderness over the radial head. It is on the lateral side of the elbow, just distal to the lateral epicondyle. If you suspect a fracture of the radial head, use a shoulder sling for immobi-

lization. If necessary for patient comfort, you may apply a long-arm splint.

- (2) *The posterior long-arm splint should be applied from the proximal humerus to the end of the forearm, with the elbow in 90° of flexion and the forearm in neutral position. If the expedition is long and definitive care cannot be obtained, and the pain and tenderness over the radial head is minimal or moderate, the splint should be removed at five days and very slow, gentle range of motion of the elbow in flexion and extension, and pronation and supination should be started, about four times a day. The posterior long-arm splint should then be reapplied for comfort. This ROM will help prevent permanent loss of motion of the elbow. If the pain and tenderness over the radial head is severe, then a moderately severe fracture of the radial head probably is present and the posterior long-arm splint should not be removed for ROM.*

---

### L. Elbow Orthopedic Problems

1. **Elbow Sprains:** Mild sprains do occur by themselves, but moderate and severe sprains are usually associated with fractures or dislocations. Therefore, if you can diagnose no specific injury such as a fracture or dislocation, but the patient is experiencing more than mild pain or the patient cannot perform full active ROM, immobilize the elbow. Avoid flexion greater than 90° because the resultant swelling may cause vascular compromise. Then apply a sling and a swathe to provide more stability during transport.
2. **Lateral Epicondylitis ("Tennis Elbow"):** Lateral epicondylitis occurs from a partial detachment of the muscle\*\* that originates on the lateral epicondyle of the humerus. It is sometimes

---

\* This specific fracture is called a Galeazzi fracture.

\*\* the extensor carpi radialis brevis muscle

referred to as tennis elbow. It develops most commonly in individuals who perform the repetitive movements of forearm pronation and wrist extension. The injury usually develops gradually and is aggravated by lifting with the forearm in a position of pronation and the wrist in extension. Upon examination, you will find point tenderness over the lateral epicondyle. The patient's pain can be reproduced by having the patient extend the wrist against resistance with the elbow held in extension and the forearm in pronation. The treatment of lateral epicondylitis is to rest the arm from the repetitive movements of forearm pronation and wrist extension.

### 3. Elbow Dislocations

- a. **Posterior Elbow Dislocation:** *The shoulder and finger joints are the only joints more often affected by dislocation. Although the incidence of elbow dislocation decreases as the development of the coronoid and olecranon progresses, it is still common in the adult. Posterior and posterolateral dislocations account for about 80% to 90% of all elbow dislocations. Posteromedial dislocations are rare. The mechanism of dislocation is as follows: a fall on the outstretched hand with the arm in abduction and the elbow in extension, causing hyperextension or axial loading (stress along the long axis of the arm), which displaces the olecranon posterior in relation to the distal humerus.*
- b. *Symptoms include elbow pain, swelling, spasm, deformity and possible numbness, tingling and focal weakness of the arm. Signs include the following: the elbow is held immobile in about 45° of flexion, the forearm appears foreshortened, the olecranon is prominent posteriorly to the distal humerus, and moderate to severe swelling.*
- c. *Differentiation between dislocation and supracondylar fracture is difficult, but very important. Generally, the two epicondyles and the olecranon tip can be palpated in the same plane if a supracondylar fracture is present. On the other hand, the olecranon can be palpated displaced*

*from the plane of the epicondyles if a dislocation is present. Perform a complete neurovascular examination of the affected extremity. The most common associated nerve injury is to the ulnar nerve because it wraps around the medial epicondyle and is vulnerable during dislocation. But entrapment of the median nerve occasionally occurs, and rarely the radial nerve is affected. Vascular compromise may result secondary to brachial artery injury, compression or entrapment.*

- d. *Reduction of an elbow dislocation is not a standard skill for the Wilderness EMT. But if the dislocation is associated with a sensory and/or vascular deficit, treatment includes early reduction. But do not attempt reduction if a supracondylar fracture is suspected, because manipulation can worsen any neurovascular deficit. If the elbow cannot be reduced after two attempts or if a nerve or vascular injury is suspected, immediate evacuation is indicated. The following are accepted techniques for reduction of the posterior elbow dislocation:*

- (1) **Traction/countertraction Technique:** *An assistant immobilizes the humerus with countertraction. Apply traction distally on the forearm (with the forearm in the resting amount of pronation or supination), while the elbow is in extension. Another assistant corrects medial or lateral displacement first if present. Then continue distal traction while at the same time flexing the elbow and then applying anterior and inferior pressure to the olecranon to disengage the coronoid from the olecranon fossa. Once the capitellum slides over the coronoid, reduction occurs.*
- (2) **Parvin's Prone Technique:** *(This technique is similar to the Stimson technique for anterior shoulder dislocation reduction.) Position the patient prone (on the abdomen) on a ledge, picnic table or other suitable area. Apply downward traction on the forearm and as the olecranon begins to slip distally, flex the elbow (avoid hyperextension). No assistant is needed. This technique usually only causes the patient slight pain.*
- e. *After reduction, again evaluate neurovascular status. Assess collateral ligament integrity by*

trying to bend the forearm in the lateral and then medial direction. Note any increase in pain or opening of the elbow. There will be a firm end-point upon lateral and medial bending if there is not a complete tear of the respective collateral ligament. Lateral bending of the elbow stresses the medial collateral ligament and medial bending stresses the lateral collateral ligament. Then flex and extend the elbow through full ROM to ensure that reduction has occurred, that the elbow is grossly stable, and that there is no mechanical blockage within the joint. Incomplete reduction is usually secondary to soft tissue interposition (usually the ulnar nerve). If incomplete reduction occurs, immobilize the elbow in the most comfortable position with a long-arm posterior splint. Also if a neurovascular deficit is present, the elbow must be splinted in the position that creates the least amount of a neurovascular deficit. After successful reduction, the elbow should be immobilized with a long-arm posterior splint, elbow flexed to 90° with the forearm in neutral position. Avoid flexion greater than 90° because the resultant swelling may cause vascular compromise. A sling and swathe should be applied.

f. Other injuries may be associated with an elbow dislocation and include the following: (i) rupture of the brachioradialis muscle (the major muscle of the radial forearm), (ii) fracture of the medial epicondyle of the humerus, which becomes entrapped in the joint, requiring open reduction and internal fixation of the fracture, (iii) fracture of the coronoid process of the ulna (common); usually this fracture reduces into anatomic position once the dislocation is reduced successfully.

g. Open reduction is indicated in the following situations:

- (1) if the dislocation is associated with a major fracture,
- (2) if there is an irreducible fracture after the dislocation is reduced,
- (3) after a few unsuccessful attempts at closed reduction.

#### **h. Anterior Elbow Dislocation**

- (1) Anterior elbow dislocations are very rare, and they sometimes reduce spontaneously. The

mechanism of dislocation is a blow to the flexed elbow that forces the olecranon anteriorly out of the olecranon fossa. Associated injuries to blood vessels and nerves at the elbow are much more common than in posterior dislocations, therefore the anterior dislocation is more serious.

- (2) Symptoms include elbow pain, swelling, spasm, deformity and possible numbness, tingling and focal weakness of the arm. Signs include the following: the arm appears shortened; the forearm is elongated and held in supination with the elbow in full extension; the olecranon fossa and trochlea are palpated posteriorly; tenting of the biceps muscle tendon and brachialis muscle is prominent anteriorly. Complete avulsion of the triceps insertion is a common associated injury. Perform a complete neurovascular examination of the affected extremity. Many anterior dislocations are open, and injury to the brachial artery is common. Ulnar nerve injury is uncommon.

- (3) Reduction of an elbow dislocation is not a standard skill for the Wilderness EMT. But if the dislocation is associated with a sensory and/or vascular deficit, treatment includes early reduction. But do not attempt reduction if a supracondylar fracture is suspected, because manipulation can worsen any neurovascular deficit. If the elbow cannot be reduced after two attempts or if a nerve or vascular injury is suspected, immediate evacuation is indicated. The following is the technique accepted for reduction of the anterior elbow dislocation: an assistant applies countertraction on the upper arm; hold the forearm to keep the elbow in partial extension; then apply force posteriorly from the forearm. After reduction, follow the same treatment as described for the posterior elbow dislocation.

#### **i. Medial and Lateral Elbow Dislocations**

- (1) These dislocations are very rare. The medial "dislocation" is usually only a subluxation. Impingement of blood vessels, nerves and other soft tissues is not as common as in the more serious lateral dislocation.

- (2) *Symptoms include elbow pain, swelling, spasm, deformity and possible numbness, tingling and focal weakness of the arm. Signs include a widened appearance of the elbow with normal relative length of the arm and forearm. Perform a complete neurovascular examination of the affected extremity.*
- (3) *Reduction of an elbow dislocation is not a standard skill for the Wilderness EMT. But if the dislocation is associated with a sensory and/or vascular deficit, treatment includes early reduction. But do not attempt reduction if a supracondylar fracture is suspected, because manipulation can worsen any neurovascular deficit. If the elbow cannot be reduced after two attempts or if a nerve or vascular injury is suspected, immediate evacuation is indicated. The following is the technique accepted for reduction of the lateral or medial elbow dislocation: an assistant applies countertraction on the upper arm. Another assistant applies traction on the forearm with the elbow held mild extension and then apply pressure medially for lateral dislocation or laterally for medial dislocation. Be careful to avoid converting this dislocation into a posterior dislocation. After reduction, follow the same treatment as described for the posterior elbow dislocation.*

**j. Volkmann's Contracture**

- (1) *Any patient with a compressive dressing or cast of the upper extremity can undergo compromise in circulation to the forearm and hand that will result in Volkmann's ischemic contracture of the forearm muscles. This complication must be prevented.*
- (2) *The best treatment is prevention by employing correct splinting technique when applying the appropriate splint for the specific injury being treated. Early recognition is necessary also. Whenever a patient complains of increasing pain, a dressing or splint around the arm, forearm or hand should be removed immediately. (Swelling, numbness and tingling are symptoms that occur later, after damage has already started.) The arm should be completely examined again and another dressing and/or splint should be applied again, but modifying*

*them so that further ischemic damage will not occur.*

---

**M. Humerus Fractures**

1. Fractures of the distal humerus do occur in adults, but they are more common in children. The peak incidence is at four to eight years of age. These fractures usually are supracondylar (just above the condyles at the distal end of the humerus). They usually occur from a fall from a height with the elbow in extension. The patient complains of severe arm pain that is worse with any movement of the arm. You can usually see deformity, and swelling can develop rapidly and become severe. The most common associated neurovascular injury is to the radial artery. If the radial pulse is absent, slowly and gently flex and/or extend the elbow while someone else tries to palpate the radial pulse. If the pulse returns, immobilize immediately with a posterior long-arm splint with the elbow in the exact position that made the radial pulse return. If there is no nerve or vascular injury, the fracture should be immobilized by application of a posterior long-arm splint with the elbow as close as possible to 90° of flexion, but no more than 90° because more flexion may increase swelling. Evacuate as soon as possible.
2. Fractures of the humeral shaft are most commonly secondary to falls, rope accidents, and skiing accidents. The mechanism of fracture usually is a direct blow to the humerus or a twisting force on the arm. The patient complains of severe arm pain that is worse with any movement of the arm. This fracture is unstable and requires careful splinting.
3. Fractures of the humerus may violate the spiral groove path of the radial nerve. Trauma to the radial nerve is the most common associated neurovascu-

lar injury. The WEMT must carefully evaluate radial nerve motor function and sensation. If there is a sensory deficit or vascular injury, or a severely angulated fracture, attempt to realign the fracture before immobilization. Support the fracture site with one hand, and with the other hand grasp the two humeral condyles just above the elbow. Apply longitudinal traction gently but firmly to realign the humerus to its normal axis. After this alignment, again perform the sensory and vascular examinations. If the sensory or vascular deficit is relieved, splint the fracture as instructed below. If the deficit is still present, try to realign the fracture one more time.

4. Field treatment of the humeral shaft fracture is application of a posterior long-arm splint with the elbow in 90° of flexion and the forearm in neutral position. Then apply a sling and swathe. Evacuate as soon as possible.

#### **5. Proximal Humerus Fractures**

- a. Fractures of the proximal humerus are hard to differentiate from a shoulder dislocation. They frequently occur in skiing accidents. The mechanism of fracture frequently is a high-velocity fall onto the abducted, externally rotated arm, or a direct blow to the anterior shoulder. The patient complains of severe pain around the shoulder that is worse with any movement of the arm. Sometimes anterior humeral head dislocations accompany fractures of the proximal humerus. You should compare the injured shoulder to the uninjured shoulder, and inspect and palpate for fullness just inferior to the distal one-third of the clavicle (a sign of an anterior shoulder dislocation).

- b. If you think the patient has both an anterior shoulder dislocation and a fracture near the humeral head, you may still want to reduce the dislocation. Certainly, if you find evidence of nerve or vascular injury and definitive care is more than two hours away, you should attempt reduction. Premedication of the patient with a short-acting narcotic or benzodiazepine can be extremely helpful. Use the standard traction-countertraction method described for anterior shoulder dislocations. However, you may also need to apply firm direct anterior pressure on the humeral head to guide it back into the proper place. The field management of an uncomplicated proximal humerus fracture is simply a sling and swathe. Evacuate as soon as possible if you identify a nerve or vascular injury.

---

### **N.Shoulder Orthopedic Problems**

#### **1. Shoulder Dislocations**

- a. The shoulder joint is where the humeral head sits in the glenoid fossa of the scapula. It is also called the glenohumeral joint. The shoulder joint is a ball-and-socket type of joint. The size of the glenoid fossa of the scapula (the socket) is 1/3 the size of the articular surface of the humeral head (the ball). This anatomy allows great range of motion, but it also predisposes the shoulder to dislocation. Supporting structures include the joint capsule, the coracohumeral, transverse, and glenohumeral ligaments, the biceps tendons and the rotator cuff.\* The shoulder is the most commonly dislocated large joint in the body. In the

---

\* The rotator cuff is comprised of the tendons of many arm and shoulder muscles; see "rotator cuff tears," below, for more.

wilderness, most dislocations occur from trauma. Depending on the mechanism of trauma, the dislocation may be anterior, posterior or inferior, although anterior dislocations are by far the most common. Always remember to perform a complete examination of the entire upper extremity.

**b. Anterior Dislocation**

- (1) Approximately 95% of all shoulder dislocations are anterior. Approximately 70% of all dislocations occur in patients under 30 years of age. Anterior dislocations occur commonly from skiing accidents as the patient crosses the ski tips or falls forward on a mogul and lands face first with the arms in the abducted, externally rotated position. They also occur during kayaking when doing a "high brace" and the end of the paddle over the head hits a tree branch or rock. The usual mechanism of dislocation is as follows: abduction and external rotation of the arm ("throwing a baseball" overhand), with a blow to the posterior shoulder or a fall on the outstretched arm. As the humeral head dislocates anteriorly, the anterior joint capsule and glenohumeral ligaments, and the rotator cuff rip. In healthy or younger patients, strong bone and inherent weakness in these structures more often results in dislocation with no fracture. Often these structures do not heal well after the dislocation is reduced. Therefore, some people will have recurrent dislocations that require surgical repair. In the elderly, the mechanism of dislocation often results in fracture instead or in addition, due to bone weakness.
- (2) The rate of recurrent anterior dislocation is about 80% if the first dislocation is sustained before 20 years of age. The recurrence rate gradually falls in the older population, because older people generally are less active. Much less force is required to dislocate a shoulder that has been dislocated previously. Some patients will have recurrent dislocations with trivial trauma or even certain movements of the shoulder.
- (3) Symptoms include shoulder pain, spasm, deformity, and possible numbness, tingling, or focal weakness of the arm. Signs include the following:
  - (a) The patient sits, holding the arm away from the chest wall, abducted and externally rotated with the elbow flexed.
  - (b) Any attempt to bring the arm across the chest (passive adduction and internal rotation) causes pain.
  - (c) Asymmetry of the injured shoulder compared to the uninjured shoulder (the normal rounded contour of the shoulder is replaced by a sharp angular outline, and you can palpate the humeral head anterior and inferior to its normal position).
  - (d) You can feel a palpable defect in the lower lateral aspect of the shoulder (beneath the acromion, especially in the posterolateral aspect where the deltoid is less tense).
  - (e) The most important sign is that the patient cannot bring the injured arm across the chest due to pain and mechanical blockage. If the patient actively or the examiner passively can bring the injured arm across and up against the chest (adduction and internal rotation), the injury is probably a fracture or a severe fracture-dislocation of the humeral head. If so, do not attempt reduction unless there is nerve or vascular deficit.
- (4) Perform a complete neurovascular examination of the affected extremity. Specifically note the function of the axillary and musculocutaneous nerves because these nerves are the



most commonly injured in anterior dislocations. (They provide sensation to the "patch area" of the shoulder and the forearm, respectively.)

**c. Reducing Anterior Shoulder Dislocations**

- (1) The standard of care in the wilderness is to reduce anterior shoulder dislocations even if no neurovascular deficit. However, you should not attempt reduction more than three times unless there is an associated sensory or vascular deficit. If you cannot reduce the shoulder after three attempts, or if you suspect nerve or vascular injury, evacuate immediately.

**(2) Which Method?**

- (a) There several methods for reduction of shoulder dislocations; all work. However, some are easier and less likely to cause additional injury.
- (b) Two well-known methods are not acceptable for Wilderness EMT use. These methods are the Hippocratic or "dirty sock" method and the Kocher maneuver. Because both "lever" the humeral head back into the glenoid fossa to achieve reduction, there is risk of causing a fracture or neurovascular injury, or to worsen any prior injury, even if performed correctly. Some authors, however, hold that the "dirty sock" method is acceptable for young, well-muscled individuals, who are unlikely to have weak bones; indeed, one respected article recommends it for such use.
- (c) The goal in selecting a reduction method is to choose one that you can comfortably perform in the wilderness environment, is unlikely to cause additional injury, and will cause the least amount of pain. If the shoulder cannot be reduced after two attempts or if a nerve or vascular injury is suspected, evacuation is indicated.
- (d) A review of popular wilderness medicine textbooks reveals the following suggestions for the reduction of dislocated shoulders: Auerbach, *Medicine for the Outdoors*

(Revised and Updated Edition)<sup>12</sup>: lateral traction-countertraction method first, then Modified Stimson (anterior traction); Bezruchka, *The Pocket Doctor*<sup>13</sup>: Modified Stimson (anterior traction) method only; Christensen, *Wilderness first aid: A resource manual for outdoor leaders in British Columbia*<sup>14</sup>: Modified Stimson (anterior traction) method, then Hippocratic, then Kocher; Darvill, *Mountaineering Medicine*<sup>15</sup>: Modified Stimson (anterior traction), then Hippocratic; Forgey *Wilderness Medicine*, 3E<sup>16</sup>: Modified Stimson (anterior traction) method only. Bowman, *Outdoor Emergency Care*: reduction not discussed; Gill, Simon and Schuster's *Pocket Guide to Wilderness Medicine*<sup>17</sup>: Modified Stimson (anterior traction) method only; Lentz, MacDonald, and Carline, *Mountaineering First Aid*, 3E<sup>18</sup>: reduction not recommended; Steele, *Far From Help! Backcountry Medical Care*<sup>19</sup>: Modified Stimson (anterior traction) method first, then lateral traction-countertraction or Hippocratic methods; Tilton and Hubbell, *Medicine for the Backcountry*<sup>20</sup>: lateral traction-countertraction, then modified Stimson (anterior traction), and warns against Hippocratic method; Wilkerson, *Medicine for Mountaineering*<sup>21</sup>: lateral traction-countertraction method and modified Stimson (anterior traction) method.

- (e) A recent article reviewed shoulder dislocation reduction methods and concluded that all methods have similar success rates. The authors recommend that the Milch (upward traction) method be attempted first because it is least painful and least likely to cause fracture or neurovascular injury. If the Milch method fails, the authors recommend the Modified Stimson (anterior traction) method, especially for obese or frail patients.<sup>22</sup>
- (f) The method that is least likely to cause additional injury is the Milch (upward traction) technique. The Modified Stimson (anterior traction) method is attractive because the patient can be positioned prone and

*weights used for traction, instead of having to apply traction yourself. A modified lateral traction-countertraction method is appropriate in certain circumstances, because they can be performed by one person and without a ledge, table or similar elevation.*

**(3) Acceptable Methods to Reduce Anterior Shoulder Dislocation**

- (a) The following are accepted techniques for reduction of the anterior shoulder dislocation. But remember, the specific methods you are allowed to perform are dictated by your medical director.
- (b) **Milch (Upward Traction) Technique:** Position the patient supine (on the back), preferably with the back elevated 30°. Place the arm in the overhead position, hand behind the head. Apply gentle traction on the flexed elbow, while gently guiding the humeral head over the glenoid fossa rim with the other hand. Occasionally, you may need to rotate the arm back and forth slightly. You may have an assistant pull countertraction at the feet or chest.
- (c) **Modified Stimson (Anterior Traction) Technique:** Position the patient prone (on the stomach) on an elevated surface to allow the shoulder to dangle straight down. Place a pad on the edge of the surface for comfort if possible. Hang 10 to 20 pounds of weight from the wrist or elbow for 15 to 30 minutes. Sometimes you will need to gently rotate the arm to disengage the humerus from the glenoid rim. (Hanging weight from the wrist requires a suitable ledge, bench or other improvisation that may not be available in some wilderness areas. Hanging weight from the elbow requires less weight and may be more practical, but you must pad the elbow well and continuously monitor

neurovascular status during the reduction.

- (d) **Lateral Traction with Countertraction Technique:** Position the patient supine on a ledge or bench, ideally at your waist level. An assistant applies countertraction with a blanket, parka, sling, or other improvisation. The assistant applies this to the intersection of the chest and axilla (armpit). You pull on the proximal forearm with the elbow is flexed to 90°, and the shoulder abducted to 45°. You may want to place a blanket, parka, or sling tied end-to-end around the inside of the patient's flexed elbow and your hips. This will make it much easier to apply firm, strong, constant traction for the long period of time it sometimes takes. You may want to rotate the arm back and forth slightly to help achieve reduction.
- (e) There are several helpful wilderness modifications to the lateral traction-countertraction method. The wilderness environment seldom cooperates to provide the equivalent of an Emergency Department cot for you. You may not have an assistant provide countertraction. You can improvise. For instance, you can use the patient's life vest to provide countertraction. If you are reducing the right shoulder, place your left leg under the patient's head, and place your toes into the arm hole of the patient's vest. Another possibility is to use a tree for countertraction by placing the countertraction parka, sling, or other item around the tree. You can also use your well-padded foot against the patient's chest for countertraction, but this position is very uncomfortable for most people. Another modification is the "Eskimo technique." The native Inuit of Greenland use kayaks and suffer

frequent shoulder dislocations. The technique is simple. Place the patient on the uninjured side so that the dislocated shoulder is up. Stand over the patient with one foot on either side. Grasp the arm and lift. The patient's body provides countertraction that is in proportion to the patient's body size.

- (f) **External Rotation Technique:** Position the patient supine with the injured arm in adduction (close to the side of the chest). Flex the elbow to 90°. Support the forearm by gently grasping the wrist with one hand and the elbow with the other hand. Using the grasped wrist as a guide, rotate the humerus externally by allowing the forearm to "fall" under its own weight. Avoid any additional external rotation at the wrist. The minimal force applied serves to avoid excessive torque and its associated complications. This maneuver avoids any traction. The hand at the patient's elbow functions only to prevent abduction (the elbow moving out away from the lateral chest). Sometimes it is difficult to know when the dislocation reduces because the procedure is usually gentle and relatively painless. Often you cannot hear or feel the reduction. Therefore, continue external rotation until the forearm is in the same plane as the body (the coronal plane).
- (4) When reduction occurs, the patient often experiences a marked reduction in pain, and you may feel or hear a "clunk." If none of these occurs after you properly apply a technique, attempt to bring the arm across the chest. If the arm moves easily without a lot of pain, it is probably reduced. Although neurovascular injury is uncommon, you must again evaluate neurovascular status after reduction, specifically the axillary and musculocutaneous nerves. Immobilize in a sling and swathe.
- d. **Posterior Shoulder Dislocation**
- (1) *Posterior dislocations account for 0.5% to 1.5% of all shoulder dislocations. The low incidence of this dislocation is secondary to the following: (i) the glenoid fossa is tilted at a 45° angle medially on the thorax, (ii) the glenoid rim fits directly behind the humeral head, and (iii) the muscles of the rotator cuff are heavier posteriorly (the supraspinatus, infraspinatus and teres major muscles). It is the most commonly missed major dislocation. The mechanism of dislocation is as follows: a violent, direct force applied to the anterior shoulder, or a violent, internal rotational force to the arm with components of adduction and flexion. This latter mechanism usually occurs when a patient has a grand mal seizure.*
- (2) *Symptoms include shoulder pain, spasm, deformity and possible numbness, tingling and focal weakness of the arm. Signs include the following: (i) the patient's arm is held/locked in adduction and internal rotation, (ii) abduction and external rotation are blocked and passive ROM causes pain, (iii) the shoulder exhibits anterior flatness and posterior fullness, and (iv) the coracoid process (normally not palpable where it lies below the anterior shoulder) is more prominent. Perform a complete neurovascular examination of the affected extremity. Specifically note the function of the axillary and musculocutaneous nerves because these nerves are the most commonly injured in anterior dislocations. Associated injuries include: (i) rotator cuff tear, weakness or detachment (subscapularis muscle); and (ii) associated avulsion fractures of the glenoid fossa or proximal humerus.*
- (3) *Treatment includes early reduction, but should not be attempted more than three times unless there is an associated sensory or vascular deficit. If the shoulder cannot be reduced after three attempts or if a nerve or vascular injury is suspected, immediate evacuation is indicated. The following are accepted techniques for reduction of the posterior shoulder dislocation:*

- (a) the Modified Stimson (Anterior Traction) technique as described for anterior dislocation, or (ii) apply traction with the arm in adduction, with concomitant direct anterior pressure on the posteriorly displaced humeral head. Although neurovascular injury is uncommon, one must again evaluate neurovascular status after reduction, specifically the axillary and musculocutaneous nerves. The shoulder should be immobilized by sling and swathe.

#### e. Inferior Shoulder Dislocation

- (1) The inferior shoulder dislocation is uncommon, but the injury is very severe. The mechanism of the dislocation is severe hyperabduction of the arm. This dislocation is always accompanied by severe rotator cuff tear or detachment.
- (2) Symptoms include shoulder pain, spasm, deformity and possible numbness, tingling and focal weakness of the arm. Signs include the following: (i) the arm is held in 180° of elevation (extreme abduction) ; (ii) the arm appears shortened; (iii) the humeral head is palpated along the lateral chest wall. Neurovascular injury is common secondary to compression of the inferior structures by the humeral head. Perform a complete neurovascular examination of the affected extremity. Specifically note the function of the axillary and musculocutaneous nerves because these nerves are the most commonly injured in anterior dislocations.
- (3) Treatment includes early reduction, but should not be attempted more than three times unless there is an associated sensory or vascular deficit. If the shoulder cannot be reduced after three attempts or if a nerve or vascular injury is suspected, immediate evacuation is indicated. The following is the technique for reduction of the inferior shoulder dislocation: Countertraction is applied in the supraclavicular region on the dislocated side. Traction is applied on the distal humerus in the longitudinal axis superiorly; then the arm is adducted inferiorly in an arch motion.
- (4) Although neurovascular injury is uncommon, one must again evaluate neurovascular status after reduction, specifically the axillary and musculocutaneous nerves. The shoulder should be immobilized by sling and swathe.
- (5) If reduction of the shoulder dislocation cannot be accomplished, it must be securely immobilized and the patient evacuated as soon as possible. Immobilizing a shoulder dislocation is difficult because the patient is usually holding the arm in a fixed position to minimize pain, away from the chest wall. The joint must be splinted in the position that is most comfortable for the patient. Any attempt to bring the arm in toward the chest wall will produce pain. One can overcome this difficulty in splinting that this fixed position of the arm produces by gently placing a pillow or rolled blanket between the arm and the chest wall to fill up the space between them. Once the arm is stabilized against the rolled blanket, the elbow can be flexed to 90° without causing any further pain. A sling and swathe can then be applied to securely immobilize the shoulder dislocation.

2. **Rotator Cuff Tears:** The rotator cuff of the shoulder consists of the tendon insertions of the subscapularis, supraspinatus, infraspinatus and teres minor muscles. These tendons blend together and attach to the greater and lesser tuberosities of the humerus. They start abduction of the arm, and control internal and external rotation at the shoulder. A fall or any other mechanism that applies indirect force to the shoulder can produce a rotator cuff tear. The symptoms of acute rotator cuff tear are shoulder pain and inability to abduct the shoulder or at least increased pain on abduction. The patient is able to shrug the shoulder. Rotator cuff tears are treated with sling immobilization. Large rotator cuff tears require surgical repair.

#### 3. Acromioclavicular Joint (AC Joint) Sprains

- a. The acromioclavicular (AC) joint is injured most commonly by a blow on top of the shoulder, driving the scap-

ula away from the distal end of the clavicle. The first-degree AC joint injury is an incomplete sprain of the ligamentous capsule between the acromion and the clavicle. There is point tenderness over the AC joint, but you cannot see or feel any elevation of the end of the clavicle.

- b. The second-degree AC joint injury is a complete sprain and therefore disruption of the ligamentous capsule between the acromion and the clavicle, but the coracoclavicular ligaments remain intact. There is point tenderness over the AC joint, and you can feel or see elevation of the distal clavicle. For a second degree sprain, the elevation of the clavicle relative to the acromion should be about one-half the diameter of the clavicle.
- c. The third-degree AC joint injury is a complete disruption of the ligamentous capsule between the acromion and the clavicle as well as the coracoclavicular ligaments. There is obvious tenderness over the AC joint as well as obvious deformity. You will see and feel the end of the clavicle coming up to as much as two centimeters above the acromion.
- d. Treatment of any AC joint injury is a sling, because use of the arm will stress the AC joint and increase pain. The sling must apply gentle upward support to the olecranon process of the ulna to be effective. For second-and third-degree AC joint injuries, a swathe is also helpful. Leave the fingers exposed so you can do sensory and vascular examinations intermittently. As long as the individual can tolerate the pain, evacuation is not mandatory.

4. **Scapula Fractures:** *Fractures of the scapular occur infrequently because it is surrounded by large muscle groups. Scapular fractures occur during a violent trauma to the back, usually directly over the scapula. Because the force required to fracture the scapula is very large and*

*the thoracic cage lies just beneath it, the patient suspected of having a scapular fracture must be carefully evaluated to detect other common associated injuries, such as pneumothorax, flail chest, fractured ribs, respiratory insufficiency and respiratory failure. The patient will limit movement of the associated arm because of severe pain at the fracture site. The signs of scapular fracture include abrasions, contusions, swelling and tenderness around the scapula as well as signs of respiratory difficulty.*

## 5. Clavicle Fractures

- a. Fractures of the clavicle most commonly occur in the middle and lateral thirds. The mechanism is usually a direct blow to the clavicle, a fall onto the lateral shoulder, or a fall onto the outstretched hand. These fractures frequently occur during snow skiing. The patient complains of shoulder or anterior, superior chest pain that is often only poorly localized. The patient may hold the injured arm against the chest wall and support the elbow and forearm with the opposite hand to "splint" the site of injury. Motion of the arm or shoulder on the side of the fracture exacerbates this pain. The patient may also complain of shortness of breath and deep pain upon cough and inspiration. Occasionally the skin is tented or even pierced because the clavicle lies just beneath the skin. The clavicle lies directly over the major arteries, veins and brachial plexus that supply the upper extremity, and thus fractures of the clavicle may damage these structures.
- b. Although a rare complication, a pneumothorax can occur from a clavicle fracture, when the fractured clavicle displaces posterior into the top of the lung. Carefully auscultate for normal, symmetrical breath sounds. Examine the skin carefully, because 3 to 5% of clavicle fractures are open.
- c. If you suspect a pneumothorax or a nerve or vascular injury, or if it is an

open fracture, evacuate immediately. Field treatment is the sling to support the fracture, as well as judicious use of analgesics. (Special "figure-8" straps designed for clavicle fracture actually cause more pain and do nothing for reducing the fracture.)

## 6. Sternoclavicular Joint Dislocation

- a. *The most common dislocation of the sternoclavicular joint is the displacement of the medial head of the clavicle anterior to the manubrium (main part) of the sternum. This joint is usually dislocated or strained by a fall onto an abducted shoulder, but a direct blow to the sternum also may produce this injury as well as rib fractures. The patient complains of pain in the region of the superior sternum and frequently will have increased pain upon taking a deep breath or when coughing. Anterior dislocations should be managed with a sling and swathe.*
- b. *Posterior dislocations are much less common than anterior dislocations, but they are much more serious. They are emergencies. A step-off between the sternum and medial head of the clavicle (compared with the uninjured side) confirms this diagnosis. The posteriorly dislocated clavicular head may create significant pressure on the esophagus and/or superior vena cava. The patient may complain of difficulty swallowing and/or present with engorgement of all the veins of the face and upper extremities, respectively. This latter problem is called superior vena cava obstruction syndrome.*
- c. *Reduction of the posterior dislocation should be attempted as soon as possible. The patient should be placed on a firm surface, and a large roll of clothing or other firm object should be placed between the scapulae. Strong, firm pressure directed posteriorly should be applied on the anterior aspect of each shoulder. If the initial reduction attempt is unsuccessful, this maneuver may be repeated with a larger object placed between the scapulae. If reduction is still not successful, the midshaft of the clavicle may be grasped with a towel clip, pliers or other feasible tool and forcefully pulled out of the thoracic cavity. The posterior dislocation requires evacuation.*

## O.Hip and Thigh Orthopedic Problems

### 1. "Hip Pointers"

- a. (reserved)

### 2. Thigh Strains

- a. (reserved)

### 3. Hip Dislocations

- a. *The hip joint is a very stable ball-and-socket joint that dislocates only after significant injury. Virtually all dislocations of the hip are posterior. The femoral head displaces posteriorly, coming to lie in the muscles of the buttock. Dislocations most commonly occur from a vehicle accident, but also may occur during falls and skiing or sledding accidents. The mechanism of dislocation is axial loading of the femur through a direct force to the knee during adduction of the leg. The patient complains of severe pain and tenderness around the hip. The injured thigh may appear shortened. The patient lies with the hip flexed (the knee drawn up toward the chest), the thigh rotated inward and adducted across the midline of the body, over the thigh of the unaffected leg. In thin patients, you can palpate the femoral head lying deep to the muscles of the buttock. Any hip motion increases the pain and is met with great resistance. Without X-ray, it is impossible to determine if there is an associated acetabular fracture.*
- b. *Anterior dislocations are rare. This dislocation is produced by wide abduction of the hip as a result of a significant force. The patient complains of severe pain and tenderness around the hip. The patient lies with the hip extended, the thigh rotated outward and abducted, and pointing away from the midline of the body. Any hip motion increases the pain and is met with great resistance.*

- c. Carefully position the patient supine, and do a complete survey of all organ systems, including the cervical spine. Accidents that produce a hip dislocation are high impact and usually produce multiple injuries, some life-threatening. Perform a complete examination of the pelvis, hip, thigh, knee and calf, including a neurovascular examination, and a cursory examination of the remainder of the injured leg to rule out any associated injuries. Posterior dislocation is commonly associated with injuries of sciatic nerve. When the head of the femur is forced out of the acetabulum, it damages the sciatic nerve by compressing or stretching it.
- d. You may attempt closed reduction, but only under the following circumstances:
  - (1) the victim cannot be evacuated to definitive medical care for more than six hours;
  - (2) there is no obvious fracture of the affected leg; and
  - (3) there is no neurovascular deficit.
- e. Place the victim supine on a flat, hard surface. Premedication with a short-acting narcotic or a benzodiazepine can be extremely helpful. An assistant must stabilize the pelvis by placing both palms on the anterior iliac crests. You must bend the knee to 90° and apply longitudinal traction with the hip flexed 30° to reduce a posterior dislocation.\* If this fails to reduce the hip after two attempts, you must evacuate emergently. There is a direct relationship between the time to successful reduction and the incidence of necrosis of the head of the femur. This complication can be devastating.

---

\* You must bend the knee to 90° and apply in-line traction with the thigh to reduce an anterior dislocation.

---

## **P. Femur Fractures**

1. The most common mechanisms for a femur fracture is a fall from a height, or high-velocity accidents during snow or water skiing. Fractures of the proximal femur occur in the femoral neck or just below. The patient will complain of pain around the proximal thigh, but also around the hip and medial aspect of the thigh. Occasionally the pain is referred to the knee.
2. There is usually minimal visible swelling or deformity. Usually the leg is shortened and externally rotated. Any movement of the leg will produce pain. Realign the leg from the its deformed position with very gentle, slow but firm longitudinal traction and then apply a Kendrick, Thomas, REEL or Hare Traction splint. Carefully and well-pad the buttock area and proximal femur area so that excessive pressure and further injury does not result from the ring or other support of the traction splint. If possible, transport the patient on a well-padded backboard. If you do not have a traction splint, you may often use a Stokes litter and a few slings to improvise, using the litter itself as a traction splint.
3. Even with the best-padded ankle hitches, traction splints tend to cause pressure necrosis when used for a long period of time. You must monitor carefully for signs of pressure necrosis, and readjust or take off the traction splint if the ankle shows signs of skin breakdown.
4. Many orthopedic surgeons doubt the usefulness of traction splinting for extended evacuations. Instead, they rec-

ommend a Jones' dressing: bulky padding surrounded by plaster, fiberglass, or flexible SamSplints™, and held together with elastic bandages.

5. If none of these splints are available, transport the patient supine on a well-padded backboard with the legs strapped together or with a tree limb or another reasonable substitute secured between them.
6. Fracture of the femoral neck is associated with significant risk of post-traumatic femoral head necrosis. Without an X-ray, it's not possible to tell femoral neck fractures from other fractures. Because there is evidence that emergent treatment of femoral neck fractures decreases the incidence of post-traumatic femoral head necrosis, patients who may have a proximal femur fracture must be evacuated emergently.
7. Fractures of the femoral shaft occur from the same mechanisms as proximal femur fractures. Following fracture, the large muscles of the thigh go into spasm to "splint" the unstable femur and usually shorten the thigh. The muscle spasm causes an increase in pain and deformity, sometimes with resulting angulation or rotation at the fracture site.
8. Because of the severe deformity that can occur with these fractures, bone edges or fragments may invade or compress nerves or blood vessels and produce significant damage. Treat it as an open fracture if there are any signs of an open wound.
9. There is always a significant amount of blood loss (500 cc to 150 cc) into the surrounding fracture site after a femoral shaft fracture. With open fractures the amount of blood loss is even greater because there is no tamponade effect. It is not uncommon for a patient to develop hypovolemic shock, even if the femoral shaft fracture is the patient's only injury. Be very careful in evaluat-

ing, treating and immobilizing these fractures because any extra movement or fracture manipulation could increase blood loss. Realign, immobilize by splinting, and emergently evacuate the patient as described for proximal femur fractures. Monitor the patient's vital signs closely.

10. Fractures of the distal femur frequently are intra-articular and occur from high-velocity loading when the knee is flexed. With axial loading of the femur, the patella becomes the driving wedge and the femoral condyles are impacted. A patella fracture may result, or the condyles of the distal femur may split.
11. If present, a patella fracture usually is discovered upon deep palpation. These fractures are often open because there is little soft tissue overlying this sesamoid ("in the middle of a tendon") bone. Realign the leg with longitudinal traction. If there is a distal femur fracture, you may feel crepitus and instability, but not if just the patella is fractured. Apply a long-leg posterior splint and evacuate the patient as soon as possible, and on a well-padded backboard if possible. You should evacuate any open fracture or fracture associated with a neurovascular injury emergently.

---

### **Q.Knee Orthopedic Problems**

#### **1. Sprains and Meniscus Injuries**

- a. The knee is prone to ligament injuries that range in severity from mild (first-degree) sprains to complete disruption (third-degree sprains). Sprains occur when abnormal bending or twisting occurs in the knee due to trauma. The patient will complain of pain in or around the knee, and guards the knee or is unable to walk normally. Examination shows swelling, ecchymosis, and sometimes point tenderness. If there is point tenderness over



the medial joint line, the **medial collateral ligament** has probably been sprained. If there is point tenderness over the lateral joint line, the **lateral collateral ligament** has probably been sprained. Try stressing the ligaments (by trying to bend the knee sideways). Do so with the knee flexed about 30°; this prevents the thigh muscles from splinting the knee. If you suspect a sprain, but there is no instability with the test, the patient may walk with the knee splinted in an improvised knee immobilizer. You may improvise such a knee immobilizer from several strong saplings, or metal pack stays from a large pack, and duct tape. The saplings or metal stays should extend from above the ankle to just below the groin.

- b. Two large ligaments (called the **anterior cruciate** and **posterior cruciate ligaments**) and the lateral and medial meniscus (cartilage) are important structures that lie deep inside the knee. They provide vital stability to the knee. If any of these is injured, the patient will complain of moderate or severe pain deep inside that joint that usually cannot be palpated. Examination usually reveals an effusion (excess joint fluid) in the knee, and moderate to severe pain upon any movement.
- c. Perform a complete examination of the hip, thigh, knee and calf, including a neurovascular examination, and a cursory examination of the remainder of the injured leg to rule out any associated injuries. Splint all suspected knee ligament sprains or meniscus injuries. Apply a long-leg posterior splint to immobilize the knee in extension. Usually the patient will allow slowly and carefully passive extension of the knee to allow placement of the splint in the position of extension. If you encounter resistance or severe pain on extending the knee, splint in the position of greatest comfort.

#### d. Lachman and McMurray Tests

(1) (reserved)

### 2. Knee Dislocations

- a. *Complete disruption of the knee ligaments commonly results in dislocation of the knee. Knee dislocations are obvious because of the amount of deformity present. The tibia may be dislocated in any of four directions relative to the distal femur. The most common dislocation is anterior (tibia anterior to the femur). This dislocation is an orthopedic emergency because of the high incidence of associated vascular injury secondary to tethering of the popliteal vessels along the posterior border of the tibia by the soleus (calf muscle) fascia. A knee dislocation is a high-energy injury most commonly produced by vehicular accidents and falls, and climbing, hiking and skiing accidents. Perform a complete examination of the hip, thigh, knee and calf, including a neurovascular examination, as well as a cursory examination of the remainder of the injured leg to rule out any associated injuries. Intact distal pulses do not rule out an arterial injury. Flap tears of the inner lining produced by the dislocation can produce delayed thrombosis of the popliteal artery.*
- b. *Reduction of a knee dislocation should be attempted because of the high incidence of associated vascular injury to the popliteal vessels. Position the patient supine. Premedication of the patient with a narcotic or a benzodiazepine can be extremely helpful, but should be avoided in the multiply injured patient. Assistants must stabilize the pelvis by placing both palms on the anterior iliac crests. The person attempting reduction must apply firm, gentle but strong longitudinal traction. This reduction maneuver usually is successful regardless of the direction of dislocation. Apply a long-leg posterior splint to immobilize the knee in extension after reduction. Emergency evacuation must be accomplished because of the significant risk of loss of the leg secondary to vascular injury. If possible, transport the victim on a backboard. If this reduction maneuver fails after two attempts, splint the knee in the position of greatest comfort and evacuate the victim emergently. During transport, one must antici-*

*pate the evolution of an arterial lesion or compartment syndrome.*

### 3. Patella Dislocation

- a. The patella is commonly dislocated. Generalized ligamentous laxity may predispose to this dislocation. Because of the increased femorotibial angle in females, this dislocation is more common in women. They most commonly occur during climbing, hiking and skiing accidents. The mechanism of dislocation is sudden extension and external rotation of the partially flexed knee. The patella usually dislocates laterally. Asymmetric quadriceps contraction during a fall may contribute to patella dislocations.
- b. Some patients have recurrent dislocations of the patella in which only a minor twisting of the knee will produce the dislocation, just as occurs with recurrent dislocation of the shoulder. Recurrent dislocations are common because the medial patellar tendon stabilizers are weakened.
- c. The patient complains of the acute onset of sharp, grating knee pain as the knee gives out, gives away, pops out, or locks up. The patient may have difficulty describing the event or localizing the pain specifically to the patellar area, especially if the dislocated patella already has reduced spontaneously. Most subluxations reduce spontaneously, but dislocations will have to be reduced. If the dislocation has not reduced spontaneously, the displacement of the patella produces an obvious deformity. Associated motor and vascular injuries are rare.
- d. Position the patient supine. The patella will often reduce simply by straightening the knee. If it does not reduce, apply gentle pressure to the patella during straightening of the knee. Apply a splint to immobilize the knee in extension. Keep the knee in extension with a knee immobilizer until definitive

medical care is obtained. (See above, under knee sprains, for how to improvise a knee immobilizer.) An X-ray is required to rule out small fractures that are frequently associated with this dislocation.

4. **Fractures about the Knee:** Fractures about the knee can occur at the distal end of the femur, at the proximal end of the tibia, or in the patella. Nondisplaced or minimally displaced fractures are sometimes confused with a ligament injury because of the local tenderness and swelling. Also remember that displaced fractures around the knee may produce significant deformity and be confused with a knee dislocation.

---

## R. Lower Leg Orthopedic Problems

### 1. Tibia and Fibula Fractures

- a. The tibial plateau is the broad intra-articular surface of the upper tibia which articulates with the distal femur. The plateau can be fractured from falls or jumps from heights, or from high-energy skiing accidents. Also, severe force at an angle through the knee joint can cause tibial plateau fractures. Lateral force can produce a lateral plateau fracture and medial force can produce a medial plateau fracture. Pain and swelling around the knee from blood in the joint quickly develops and is obvious. Perform a complete examination of the thigh, knee and calf, including a neurovascular examination, as well as a cursory examination of the remainder of the injured leg to rule out any associated injuries. Observe for the signs of compartment syndrome. Because of the anatomic tethering of the popliteal artery by the calf muscle complex, arterial injuries can result from plateau fractures, especially when they are associated with knee dislocations.

- b. If there is any evidence of popliteal artery injury or any significant deformity of the fracture, realign the fracture. Apply a long-leg posterior splint to immobilize the knee in extension and the ankle in dorsiflexion. There is significant risk of loss of the leg from vascular injury or compartment syndrome, so evacuate emergently. If possible, transport the victim on a well-padded backboard. If you cannot realign after two attempts, splint in the position of greatest comfort and evacuate emergently. During transport, observe carefully for evolution of arterial compromise or compartment syndrome.

- 2. **Tibial Shaft Fractures:** Tibial shaft fractures are associated with fibula shaft fractures in 90% of cases. These fractures are usually from high-energy trauma, most commonly skiing. The tibial shaft fracture is the most common type of open fracture occurring in the wilderness. Perform a complete examination of the thigh, knee and calf, including a neurovascular examination, as well as a cursory examination of the remainder of the injured leg to rule out any associated injuries. Realign the fracture. Apply a long-leg posterior splint to immobilize the knee in extension and the ankle in dorsiflexion after realignment. You may also use a traction splint with light traction. There is a significant risk of loss of the leg due to compartment syndrome or vascular injury, so evacuate emergently. If you cannot realign after two attempts, splint in the position of greatest comfort and evacuate the victim emergently. During transport, watch for evolution of a compartment syndrome.

malleolus, distal fibula, or any combination of these. The mechanism of injury is twisting around a fixed foot. The distal tibia can fracture also from axial loading from a fall or jump. As with other joints, it can be very difficult to differentiate an nondisplaced fracture from a sprain. Carefully observe the area around the ankle for any open injury. If there is any rotational deformity of the ankle or subluxation, realign the deformity. Then immobilize the ankle and foot with a posterior short-leg splint. The patient should not bear weight. Evacuate the patient as soon as possible.

## 2. Ankle Dislocation

- a. Ankle dislocations generally occur with falls onto uneven surfaces or with twisting. Ankle dislocations are almost always accompanied by fractures of both malleoli or complete disruption of their associated ligaments. Carefully observe the area around the ankle for any open injury.
- b. Reduce ankle dislocations, because most dislocations are associated with a vascular or sensory deficit. Premedication with a short-acting narcotic or a benzodiazepine can be extremely helpful. Position the patient supine. Have an assistant hold countertraction on the distal calf. Grasp the foot with one hand on the posterior heel and the other hand on the distal, dorsal part of the foot. Have the patient bend the knee to relax the calf muscle. Pull longitudinal traction while at the same time bringing the foot into alignment with the distal tibia. Any ankle fracture or dislocation associated with an open wound must be assumed to be open treated as such. Immobilize the ankle and foot with a posterior short-leg splint or sugar tongs splint. There must be no weight bearing. Evacuate the patient as soon as possible be-

---

## S. Ankle Orthopedic Problems

- 1. **Ankle Fractures:** Ankle fractures are fractures of the distal tibia, medial

cause nerve and vascular injuries can occur.

### 3. Ankle Sprains

- a. The ankle sprain probably is the most common musculoskeletal injury occurring in the wilderness. A sprain is defined as tearing of a ligament. The lateral ligament complex usually is injured by an inversion injury and the medial ligament usually is injured by an eversion injury. Palpate the lateral and medial ligaments for tenderness and evaluate for instability by performing the anterior and posterior draw tests. This is done by stabilizing the distal tibia with one hand and grasping the posterior heel with the other, and then pulling the foot forward and backward, respectively. If the talus slides forward or backward within the ankle joint (use the uninjured ankle as a comparison), the injury is unstable and a third-degree sprain.
- b. Sprains are separated into three grades. A first-degree sprain is stretching or microscopic tearing of a ligament, resulting in mild pain, local tenderness and minimal swelling. There is no opening of the injured joint. Careful weight bearing is possible. If the patient must walk, the patient should wear a splint such as a commercially available stirrup air splint; the patient should not walk long distances or run. Taping the ankle is an alternative (see below).
- c. A second-degree sprain is severe stretching and partial tearing of a ligament, resulting in moderate to severe pain, marked tenderness and swelling. There is marked pain and sometimes partial opening upon stress testing by eversion and inversion of the ankle. There is moderate pain on weight bearing.
- d. A third-degree sprain is a complete rupture of the ligaments, resulting in severe pain, tenderness, discoloration

and swelling. The ankle commonly appears deformed and weight bearing is impossible.

- e. Second- and third-degree sprains should be immobilized with a short-leg, posterior splint or air splint. If possible, the patient should not weight bear on the leg.
- f. Lateral ankle sprains is sometimes associated with a pull-off fracture of the muscle tendon that inserts on the base on the 5th metatarsal. Upon examination, there is point tenderness at the base of the 5th metatarsal. If the patient experiences only mild discomfort while walking, treatment is wearing a good climbing boot with a stiff sole. But if the patient experiences moderate or severe pain, immobilize the foot and ankle in a short-leg posterior splint, or sugar-tongs splint.
- g. **Ankle Taping:** (reserved)

### 4. Achilles Tendinitis

- a. (reserved)

### 5. Achilles Tendon Rupture

- a. *The gastrocnemius and soleus muscles join in the middle of the calf to form the Achilles tendon. Tendon rupture most commonly occurs secondary to indirect mechanisms resulting in forceful dorsiflexion of the ankle. Initiating a sprint, slipping on a stair or ladder, or a fall from a height may result in sufficient dorsiflexion to rupture the tendon. But tendon tears also can be secondary to direct trauma from blows to a taut tendon or by lacerations.*
- b. *History suggests the diagnosis of Achilles tendon rupture. The patient experiences sudden pain, often described as a feeling like someone kicked the patient in the calf. An audible snap may be heard and the patient subsequently has severe pain and difficulty upon stepping off the foot. Physical exam reveals swelling of the distal calf as well as a palpable defect in the tendon 2 to 6 cm proximal to its insertion into the calcaneus, the location where rupture most frequently occurs. Plantar flexion of the injured ankle will be weaker and painful when compared to the*

uninjured side. Active plantar flexion of the injured side does not rule out the diagnosis of Achilles tendon rupture because other muscles can generate some plantar flexion. Additionally, the calf squeeze or "Thompson's test" will help confirm the diagnosis of complete tendon rupture. A positive calf squeeze is indicated by failure of the foot to plantar flex against gravity with calf compression when the patient is lying prone and their knee is flexed to 90°.

- c. Treatment is immobilization of the foot and ankle in a short-leg posterior splint with the ankle in a position of as much plantar flexion as possible. Do not allow the patient to bear weight during evacuation.

## T. Foot Orthopedic Problems

### 1. Tarsal Bone Fractures

- a. The calcaneus (heel bone) and talus (central bone of the ankle) are fractured most often when the patient lands on the feet during falls or jumps from a significant height. The mechanism of injury is the foot being forced into maximum dorsiflexion. With a calcaneus fracture, significant heel pain, swelling, deformity, tenderness and crepitus are evident immediately. A talus fracture usually is impossible to differentiate on history and examination from an ankle fracture or significant sprain. Theoretically, with a talus fracture, tenderness is distal to the malleoli. With an ankle fracture, there is tenderness and sometimes deformity at the level of the malleoli. Talus fractures usually are not associated with ankle fractures, but they may be associated with dislocations of the subtalar joint (between the talus and calcaneus) and the deformity will be more obvious. Fractures of the other tarsal bones are rare, you would suspect one by localizing tenderness to a specific tarsal bone.
- b. Tarsal bone fractures are associated with significant swelling but rarely with

any neurovascular injury. Immobilize the ankle and foot with a posterior short-leg splint or sugar tongs splint. The patient must not bear weight. Evacuate the patient as soon as possible, because post-traumatic necrosis of the talus bone is a common and serious complication.

- c. Frequently the force of injury that fractures the calcaneus or tarsal bones is transmitted up the legs to the spine, producing a fracture of the lumbar spine or associated disc injury. Question the patient about pelvis and back pain, as well as any other associated leg pain. Examine the lumbar and even thoracic spine completely. Evacuate any patient complaining of lower back pain supine and secured on a well-padded backboard. A patient who has sustained a disc injury usually will complain of pain, numbness or tingling down a specific part (dermatome) of one or both legs. The most common distribution of the pain, numbness or tingling is down the buttocks, the posterior thigh, and the lateral calf.

### 2. Hindfoot Dislocations

- a. The subtalar joint may be dislocated infrequently during a significant fall or jump when an individual lands off balance or on an uneven surface. The calcaneus (heel bone) may be dislocated medially or laterally relative to the talus, the later being slightly more common. Perform a complete examination of the leg, including a neurovascular examination. These dislocations occur secondary to high-energy trauma and there for associated injuries to the affected leg are common. Also, arterial and nerve injuries are common and must be diagnosed. Assess the position of the heel to the ankle.
- b. Reduction of this dislocation must be attempted if there is any sensory or vascular injury or if the patient cannot be transported to a definitive care center within two hours. Premedication of the patient with a narcotic or a benzodiazepine can

be extremely helpful, but should be avoided in the multiply injured patient. Position the patient supine. An assistant applies countertraction by holding the distal calf firmly with both hands. Then the foot is grasped with one hand on the posterior heel and the other hand on the distal, dorsal part of the foot. The knee is bent to relax the calf muscle. Finally, longitudinal traction is applied while at the same time bringing the heel into alignment over the ankle joint. Following reduction, the ankle and foot must be reexamined, including the sensory examination. Any subtalar dislocation associated with an open wound must be assumed to be an open dislocation and must be treated as an open fracture. Then immobilize the ankle with a posterior short-leg splint. There must be no weight bearing. Evacuate the patient as soon as possible because nerve and vascular injuries can occur.

- C. Medial dislocations tend to reduce more easily than lateral dislocations because in lateral dislocations, the posterior tibial tendon frequently becomes displaced on the lateral neck of the talus and the reduction is blocked. Open reduction is required. If the reduction maneuver fails after two attempts, splint the subtalar dislocation in the position of greatest comfort and evacuate the victim emergently.

### 3. Midfoot Fractures and Dislocations

- a. Midfoot (Lisfranc's) dislocations are associated generally (but not always) with one or more fractures at the base of the metatarsals, most commonly the 2nd and 5th metatarsals. Midfoot dislocations and fractures occur in accidents secondary to axial loading of the foot while it is in maximum plantar flexion. This mechanism of injury is produced most commonly with vehicular accidents and in the wilderness with snowmobiling. The patient complains of midfoot pain. There is significant swelling and tenderness at the base of the 1st, 2nd and/or 5th metatarsals. Instability and crepitus frequently are noted upon dorsal-plantar-originated force. The forefoot is sometimes displaced laterally, relative to the midfoot when the injury is unstable. More commonly, the foot is normally aligned. After the neurovascular

examination is completed, stress the forefoot by first stabilizing the heel with one hand and then apply valgus and varus stress on the forefoot with the other.

- b. If the forefoot is unstable and associated with significant pain, swelling, tenderness and/or crepitus, suspect a midfoot fracture-dislocation. Treatment is immobilization by a short-leg posterior splint. Do not allow the patient to bear weight during evacuation because severe, significant swelling, pain and further injury to the midfoot will occur.

### 4. Metatarsal Shaft Fractures

- a. Metatarsal shaft fractures occur due to crush injuries and to falls or jumps from moderate heights. They also occur as stress or so-called "march" fractures: they result from prolonged hiking or running for long distances, often due to poor preconditioning or poor foot wear. The patient experiences pain over the midfoot and there is point tenderness over the midshaft of the metatarsal(s) bone(s). The 2nd and 5th metatarsals are most commonly affected. Remember to perform a cursory examination of the affected leg to rule out any associated injuries. If experiencing only mild discomfort, the patient may walk, but walking should be kept to a minimum to control pain and swelling. The patient should walk only with a stiff-soled hiking or climbing boot. Midshaft fractures that are unstable or associated with moderate or severe pain should be treated with a short-leg posterior splint. Do not allow the patient to bear weight during evacuation.

5. **Toe Fractures:** Toe phalanges are fractured by crush injuries or when heavy objects are dropped on the foot. These injuries can be prevented by wearing steel-toed or hard-toed climbing boots. The patient experiences pain that is increased on movement. The common signs of fracture are present upon examination. Check capillary refill in the

nailbed. The great toe phalanx fracture is the worst of these fractures because the greatest amount of force is placed on the great toe during the toe-off phase of weight bearing. Treatment is taping the injured toe to the larger adjacent uninjured toe with cotton placed between them to prevent rubbing. For greatest comfort, the patient should wear a protective boot with a stiff sole and deep toe box. The patient can weight-bear if necessary, but keep walking to a minimum to control pain and swelling.

## 6. Toe Dislocations

- a. Metatarsophalangeal (MTP) joint dislocations are uncommon. They are most common in the great toe. Crush injuries and rock climbing accidents while wearing flexible-soled shoes can produce this dislocation. Wearing boots with reinforced toe boxes will help prevent it. The mechanism of dislocation is moderate axial force. Dislocations of the great toe can be associated with fractures, even open fractures, of the metatarsal or phalanx, and the dislocation generally is distal. The lesser MTP joints generally dislocate laterally or medially. The most common mechanism is striking unshod toes on immovable objects.
- b. Reduce MTP and IP toe dislocations in the wilderness to decrease pain and improve function. Reduce the dislocation by applying longitudinal traction with gentle manipulation just distal to the area of dislocation. Once reduced, tape the injured toe to the larger adjacent uninjured toe with cotton between them to prevent rubbing. For greatest comfort, the patient should wear a boot with a stiff sole and deep toe box. The patient can weight-bear if necessary, but keep walking to a minimum to control pain and swelling.

7. **Soft Tissue Injuries of the Foot and Ankle:** Remember that as in the hand, lacerations or wounds about the ankle and foot, occurring by themselves or secondary to orthopedic injuries, may damage important underlying nerves and tendons. Puncture wounds of the foot occur commonly and may cause serious infection if not treated early and correctly.

## Glossary

**Abduct:** to move away from the midline. Contrasted to Adduct, which is to move toward the midline. You can remember the root AB means "away" by remembering that ABnormal means away from normal.

**Achilles Tendon:** the calcaneal tendon. Attaches the calf muscles to the heel.

**Acromio-clavicular Joint:** at the top of the shoulder, where the acromion process of the scapula join. An acromio-clavicular ("A-C") sprain or separation is diagnosed by point tenderness over the AC joint after a fall onto the shoulder.

**Acromion:** also known as the acromion process; the projection of the scapula, at the top of the shoulder, that connects to the clavicle.

**Adduct:** To move toward the midline. Contrasted to ABduct, which means to move away from the midline.

**Anatomic Snuffbox:** a small hollow between two tendons, at the base of the thumb. The scaphoid bone can be palpated here, and persistent point tenderness here is sufficient to diagnose a fracture of the scaphoid bone. A scaphoid fracture is often invisible on X-ray, but must be casted for six weeks to allow proper healing.

**Angulate:** to form an angle. An angulated fracture has a bend where there normally isn't one.

**Avulsion Fracture:** when a strong pull by a tendon or ligament pulls off a piece of bone.

**Biceps Muscle:** the major muscle of the front of the upper arm. At the shoulder, it has two tendons and two attachments, thus the name "biceps." The "triceps" muscle has three attachments at one end.

**Bilaterally Symmetric:** one side is the mirror image of the other.

**Bolus:** A single large dose of a medication; as contrasted with a continuous infusion via an IV.

**Calcaneofibular Ligament:** the middle of the three ankle ligaments under the lateral malleolus.

**Calcaneus:** heelbone.

**Clavicle:** the collar bone.

**Collateral Ligaments:** ligaments on either side of a joint. They keep the joint from bending sideways.

**Coronal Plane:** the anatomic plane that divides the body into front and back.

**Crepitus:** crunching on palpation. Caused by broken bones or air under the skin. Also known as crepitation.

**Deltoid Muscle:** the large muscle on the lateral aspect of the shoulder. Not to be confused with the deltoid ligament under the medial malleolus at the ankle. Deltoid means shaped like a greek delta, or triangle.

**Deltoid Ligament:** the large ligament under the medial malleolus at the ankle. Not to be confused with the deltoid muscle at the shoulder. Deltoid means shaped like a greek delta, or triangle.

**DIP:** Distal InterPhalangeal (joints). The finger or toe joints nearest the end.

**Dorsiflex:** movement toward the dorsum (dorsal side). For example, dorsiflexion at the ankle means moving the foot up.

**Eponychium:** the fold of skin-like tissue around the margin of a fingernail or toenail.

**Evert:** When referring to motions of the ankle, evert or eversion refers to the movement made when trying to place the tops of both feet together, and the soles facing outward.

**External Rotation:** rotation away from the midline. When referring to motion at the ankle or hip, it means moving the toes away from the midline.

**Glenohumeral Joint:** The shoulder joint.

**Glenoid Fossa:** The "socket" of the ball-and-socket shoulder joint.

**Internal Rotation:** rotation toward the midline. When referring to motion at the ankle or hip, it means moving the toes toward the midline.

**Intra-articular:** within the joint. When referring to fractures, it means that the fracture line extends into the joint. This tends to make proper healing more difficult.

**Invert:** When referring to motions of the ankle, invert or inversion refers to the movement made when trying to place the soles of both feet together. This is the most common mechanism for an ankle sprain.

**Joint Capsule:** a fibrous sac around the joint that holds in the joint fluid (synovial fluid).

**Joint Capsule:** a thin membrane around a joint that holds in the joint (synovial) fluid.

**Joint Capsule:** The soft-tissue structures around a joint; serves to support the joint and to hold in joint fluid.

**Longitudinal:** lengthwise.

**Malleoli:** plural of malleolus. Refers to the bony prominences on either side of the ankle, formed by the distal tibia and fibula.

**Malleolus:** The bony prominences on either side of the ankle are the medial and lateral malleoli (plural is malleoli; singular is malleolus).

**MCP:** MetaCarpal-Phalangeal (joints; at the base of the fingers).

**MCP:** MetaCarpoPhalangeal (joint). The joint where a finger joints the hand.

**Olecranon:** The bony tip of the elbow.

**Osteomyelitis:** Infection of bone.

**Patella:** kneecap.

**Periosteum:** The membranous covering of a bone.

**PIP:** Proximal InterPhalangeal (joint; of a finger or toe).

**PIP:** Proximal InterPhalangeal (joint). The finger joint second from the end; between the DIP and MCP joints of the finger.

**Plantar Flexion:** at the ankle; flexing the ankle so that the foot moves downward, toward the plantar aspect (bottom) of the foot.

**Pronation:** Twisting the forearm so the palm is down.

**Radial:** toward the radius (toward the thumb). As opposed to ulnar: toward the ulna (toward the little finger).

**ROM:** Range Of Motion (of a joint).

**Scaphoid:** one of the eight wrist (carpal) bones. Also sometimes known as the carpal navicular bone (the tarsal navicular bone is found in the foot). Both words, navicular and scaphoid, refer to the bone's boat-like shape. The scaphoid bone can be palpated in the anatomic snuffbox at the base of the thumb, and persistent point tenderness here is sufficient to diagnose a fracture of the scaphoid bone. A scaphoid fracture is often invisible on X-ray, but must be casted for six weeks to allow proper healing.

**Scapula:** shoulder blade.

**Sugar Tongs Splint:** A splint, usually made from plaster, "fiberglass," or a flexible splint such as a SamSplint™. It is shaped like a long "U," and covers both sides of a limb. For the forearm and wrist, it starts at the palm, goes proximal up the forearm, around the back of the elbow, then back down the forearm to the back of the hand. For the ankle, it goes from one side of the leg, down under the foot, then up the other side of the leg.

**Supination:** Twisting the forearm so the palm is up.

**Talofibular Ligaments:** The anterior and posterior talofibular ligaments are found below the lateral malleolus at the ankle. They connect the lateral malleolus (the distal fibula) with the talus (the large tarsal bone just above the heel). The anterior talofibular ligament is the most commonly sprained ligament in ankle sprains.

**Tendon:** a dense, fibrous band that joins a muscle to a bone. Similar in appearance to ligaments that join bone to bone.



**Ulnar:** toward the ulna (toward the little finger). As opposed to radial (toward the thumb).

**Volar Plate:** A tough ligamentous plate on the volar (palm) side of each finger joint.

**Volar:** the same side of the arm as the palm.

**Whiplash:** The mechanism of injury causing many neck injuries; when the head is "whipped" forward or back on the end of the neck from sudden deceleration, as in a car accident or at the end of a climber's fall.

## References

1. Fischer RP. Cervical radiographic evaluation of alert patients following blunt trauma. *Ann Emerg Med* 1984;13:905-7.
2. Morales EM. Analysis of cervical spine injury [letter]. *Ann Emerg Med* 1986;15:1247-8.
3. Ringenberg BJ, Fisher AK, Urdaneta LF, Midthun MA. Rational ordering of cervical spine film radiographs following trauma. *Ann Emerg Med* 1988;17:792-6.
4. Roberge JR, Wears RC, Kelly M, et al. Selective application of cervical spine radiography in alert victims of blunt trauma: A prospective study. *J Trauma* 1988;28:784-8.
5. Buchulis BL, Long WB, Hynes GD, Johnson MC. Clinical indications for cervical spine radiographs in the traumatized patient. *Am J Surg* 1987;153:473-7.
6. Kreipke DL, Gillespie KT, McCarthy MC, Mail JT, Lappas JC, Broadies TA. Reliability of indications for cervical spine films in trauma patients. *J Trauma* 1989;29:1438-9.
7. Conover K. EMTs should be able to clear the cervical spine in the wilderness [editorial]. *J Wild Med* 1992;3(4):339-43.
8. Walker MD, Director, Division of Stroke and Trauma. New treatment for acute spinal cord injury. Clinical Alert. National Institute of Neurological Disorders and Stroke., 1990.
9. Iserson KV, ed. Orthopedic injuries in the wilderness III: Guidelines for individuals with advanced skills. *Position Papers 1989*. Point Reyes Station, CA: Wilderness Medical Society, 1989.
10. Warden TM. Incision and drainage of cutaneous abscesses and soft tissue infections. *Clinical procedures in emergency medicine*. Philadelphia: Saunders, 1985:997-8.
11. Barnett RC. Soft-tissue foreign body removal. *Clinical procedures in emergency medicine*. Philadelphia: Saunders, 1985:546.
12. Auerbach PS. *Medicine for the outdoors: A guide to emergency medical procedures and first aid*. Revised and Updated. Boston: Little, Brown and Company, 1991.
13. Bezruchka S. *The pocket doctor*. 2nd ed. Seattle: The Mountaineers, 1992.
14. Christensen A, ed. *Wilderness first aid: A resource manual for outdoor leaders in British Columbia*. N. Vancouver, B.C.: Wilderness First Aid and Safety Association of British Columbia, 1986.
15. Darvill FT. *Mountaineering medicine: A wilderness medical guide*. 12nd ed. Berkeley, CA: Wilderness, 1989.
16. Forgey WW. *Wilderness medicine*. 3rd ed. Merrillville, IN: Indiana Camp Supply Books, 1987.
17. Gill PG Jr. *Simon & Schuster's pocket guide to wilderness medicine*. New York: Simon & Schuster, 1991:204.
18. Lentz JM, Macdonald SC, Carline JD. *Mountaineering first aid: A guide to accident response and first aid care*. 3rd ed. Seattle: The Mountaineers, 1985.
19. Steele P. *Far from help: Backcountry medical care*. Seattle: Cloudcap, 1991.
20. Tilton B, Hubbell F. *Medicine for the backcountry*. Merrillville, IN: ICS Books, 1990.
21. Wilkerson JA. *Medicine for mountaineering*. 4th ed. Seattle: The Mountaineers, 1992.
22. Riebel GD, McCabe JB. Anterior shoulder dislocation: A review of reduction techniques. *Am J Emerg Med* 1991;9(2):180-9.